CYANOTIC CONGENITAL HEART DISEASE: TEST YOUR KNOWLEGE

Mohamed Sulaiman, MD
Pediatric cardiologist

Kidsheart: American Fetal & Children's Heart Center
Dubai Healthcare City, Dubai-UAE

Normal Cardiac Physiology

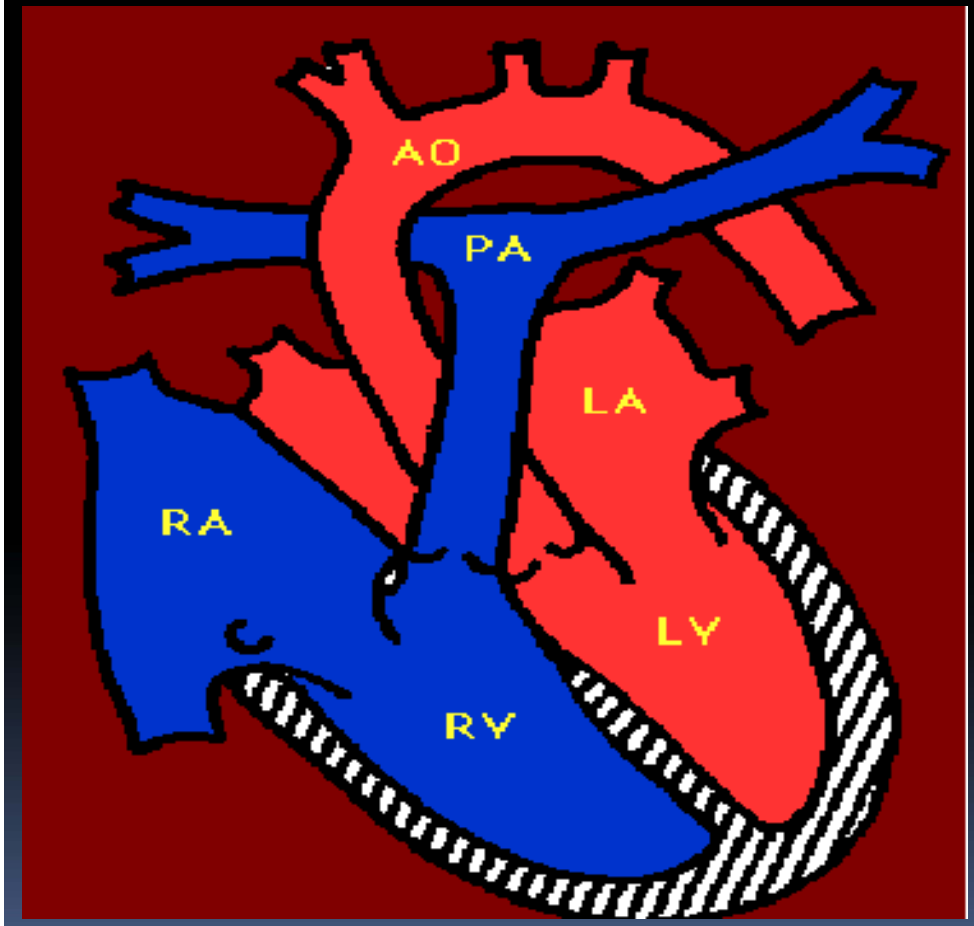

	PRESSURES	SATS
RA	3-7	70 +/- 5%
RV	25/0	70 +/- 5%
PA	25/10	70 +/- 5%
LA	5-10	97 +/- 3%
LV	100/10	97 +/- 3%
AO	100/70	97 +/- 3%

Mixing everything in real live

TACHYPNEIC POOR FEEDER: H&P (1)

- You are called to see a 24 hour-old infant who initially was doing well, but now is not feeding and is mildly tachypneic (but not in respiratory distress)
- On exam,

  His precordium is quiet, S_2 is normally split, and you heard no heart murmurs.

  His liver is mildly enlarged, abdomen soft.

  Femoral pulses are present.

TACHYPNEIC POOR FEEDER: PE & LABS

- Saturation by pulse oximeter is 90%:
- with administration of 100% FiO_2 it increases to 99%.
- Blood pressures are equal in the arms and legs.

- Electrolytes, CBC are normal
- You suspect either sepsis or CHD.

TACHYPNEIC POOR FEEDER: PE & LABS

- Saturation by pulse oximeter is 90%:
- with administration of 100% FiO_2 it increases to 99%.
- Blood pressures are equal in the arms and legs.

- Electrolytes, CBC are normal
- You suspect either sepsis or CHD.

TACHYPNEIC POOR FEEDER: PE & LABS

- What is the one test that would lead you to the correct diagnosis?
  - A. CXR
  - B. 12 Lead Electrocardiogram
  - C. Simultaneous hand and foot pulse oximetry determinations
  - D. Arterial blood gas on room air

    On 100% FiO_2

TACHYPNEIC POOR FEEDER: PE & LABS

- What is the one test that would lead you to the correct diagnosis?
  - A. CXR
  - B. 12 Lead Electrocardiogram
  - C. Simultaneous hand and foot pulse oximetry determinations
  - D. Arterial blood gas on room air

    On 100% FiO_2

Think for a minut

- Cyanosis: NOT PROMINENT
- Equal blood pressures
- The findings of femoral pulses

TACHYPNEIC POOR FEEDER: MANAGEMENT

- The most appropriate management of this infant is:
  - A. STAT ECHO
  - B. Start PGE, intubate, hyperventilate
  - C. Start PGE, put in head hood with 40% FiO_2
  - D. Start PGE, leave in room air
  - E. Start PGE, leave in room air plus AB

TACHYPNEIC POOR FEEDER: MANAGEMENT

- The most appropriate management of this infant is:
  - A. STAT ECHO
  - B. Start PGE, intubate, hyperventilate
  - C. Start PGE, put in head hood with 40% FiO_2
  - D. Start PGE, leave in room air
  - E. Start PGE, leave in room air plus AB


** RR
HIGH
POSTDUCTAL
PREDUCTAL
100
93
59
87

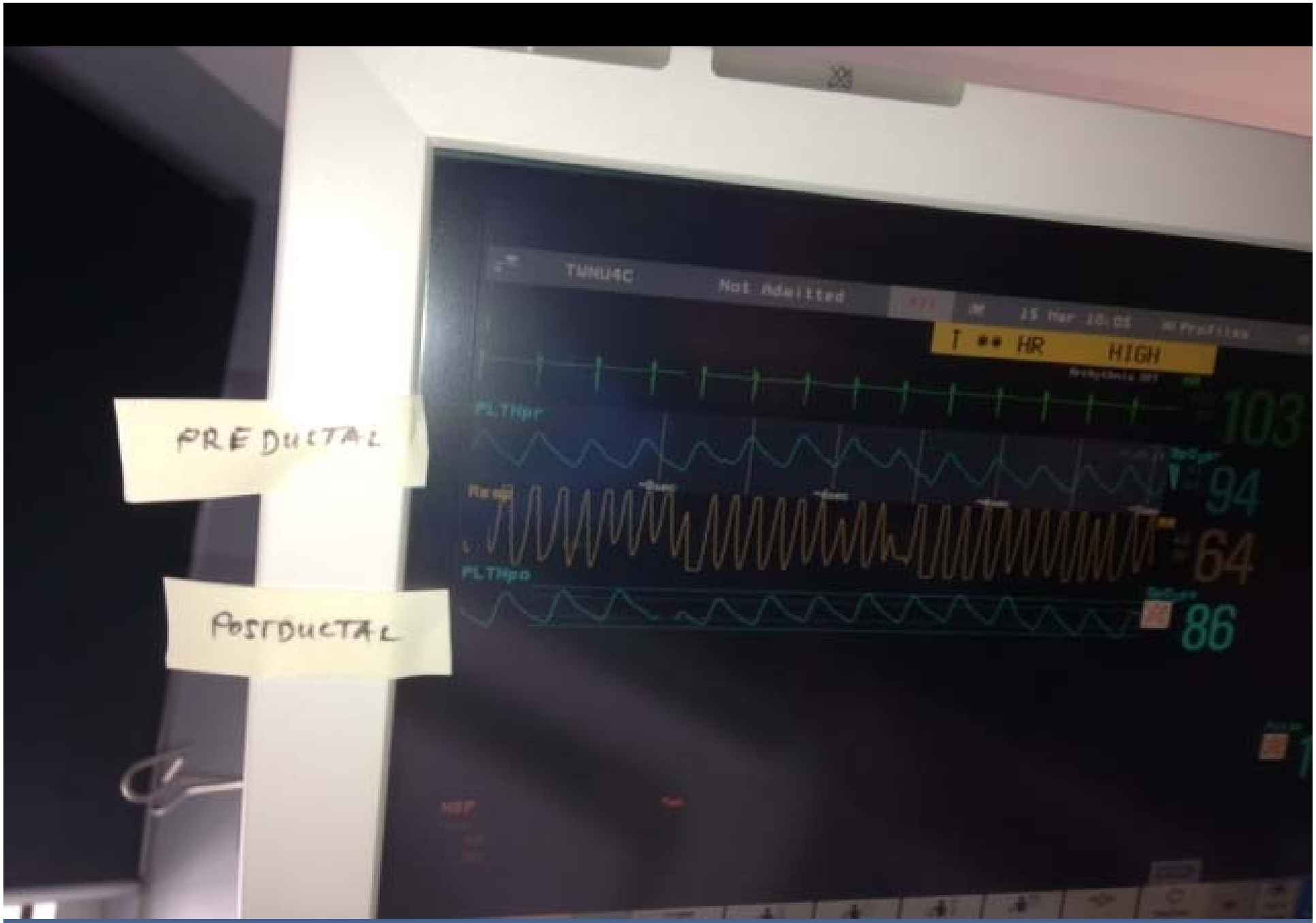
PREDUCTAL
POSTDUCTAL
TWNU4C
Not Admitted
HR
HIGH
103
94
64
86

Why is that: CAVC with discrepancy in the sat

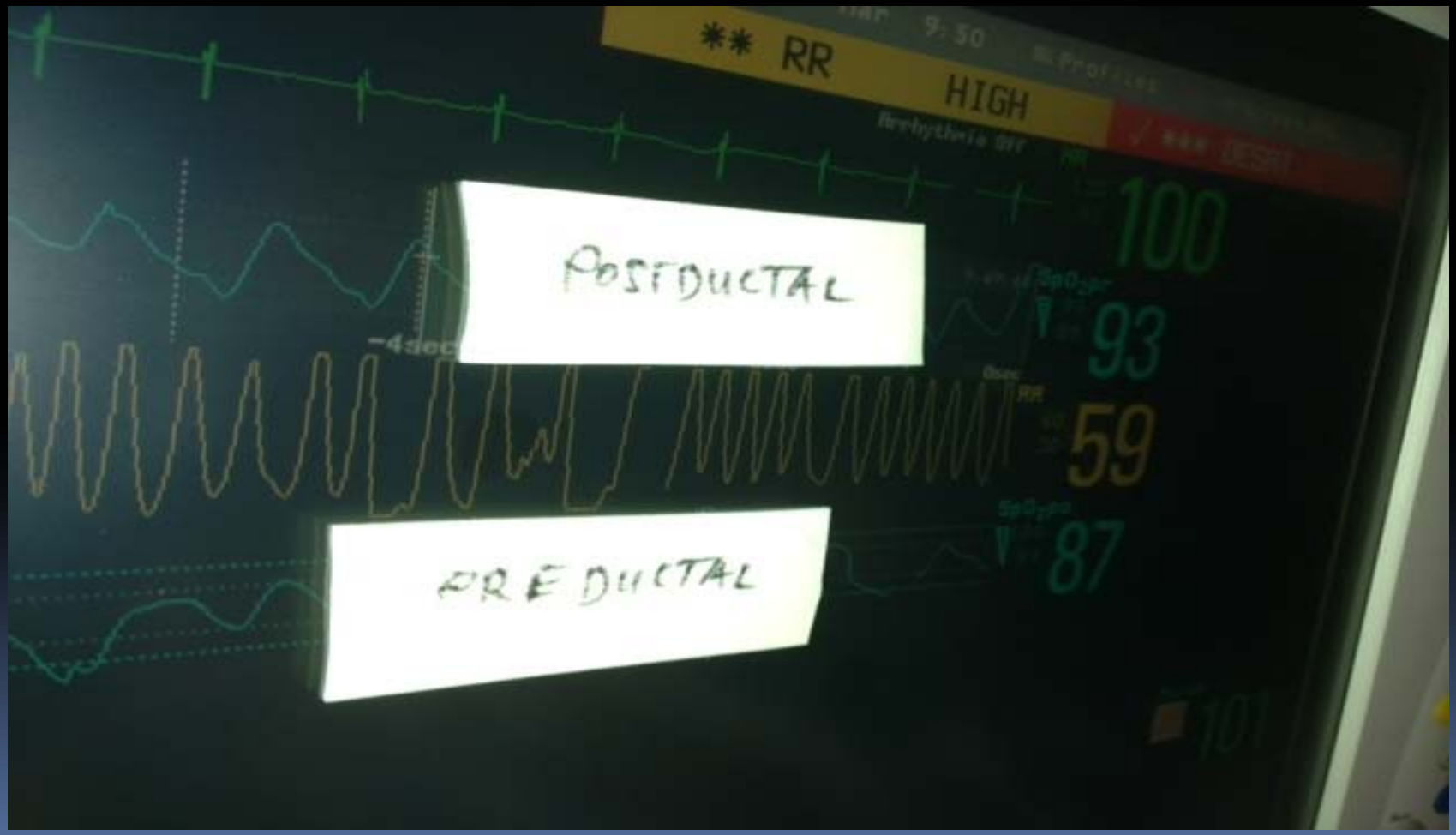

TACHYPNEIC POOR FEEDER - PULSE OXIMETRY

In this infant, which pulse oximetry findings are consistent with critical coarctation of the aorta?

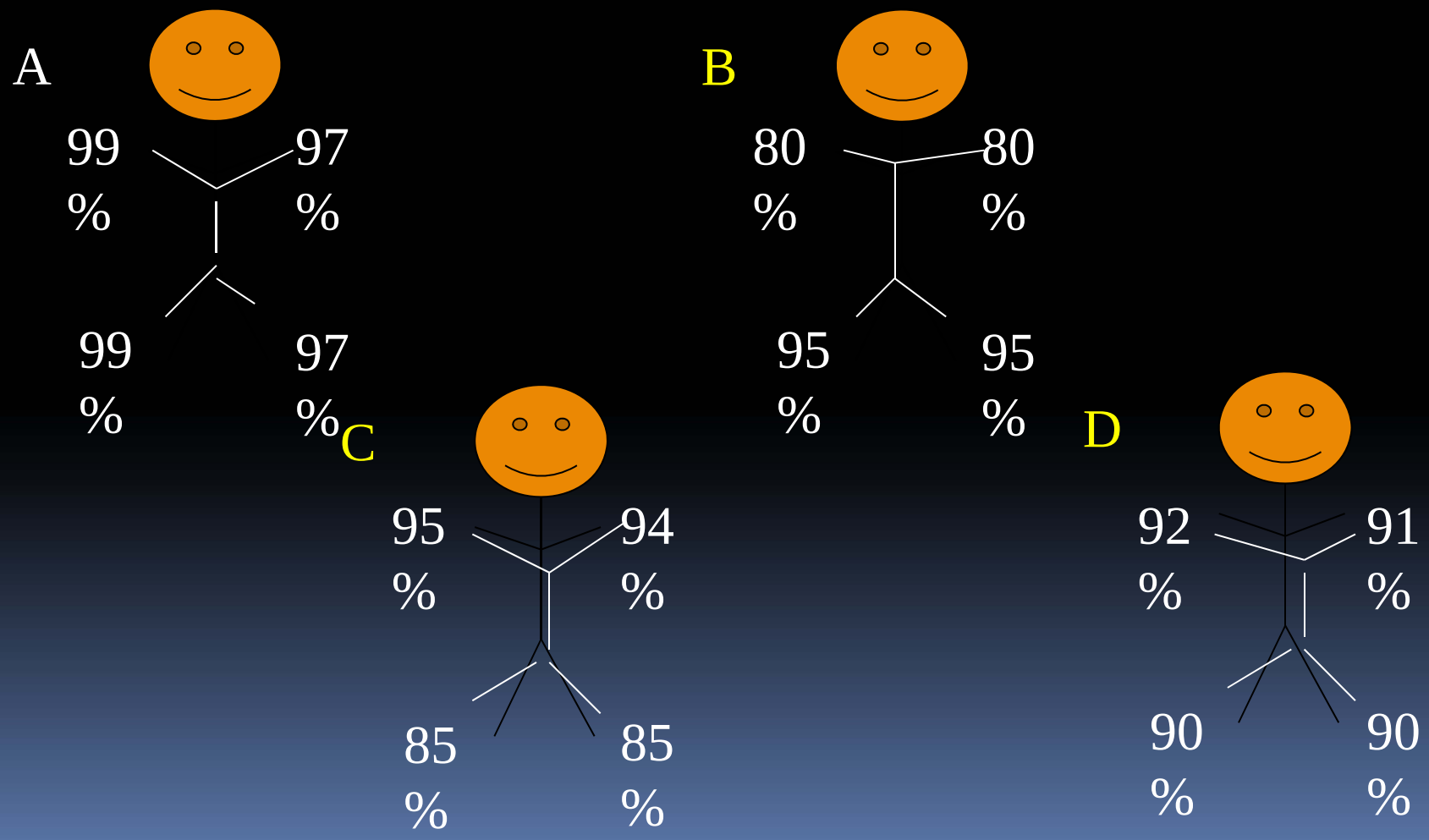

Cyanosis

Which patient has HLHS out of triplet?

- A

- C

Next Case:

- Next day: does not want to eat, saturation: 95 %, breath fast, Lactate 7.

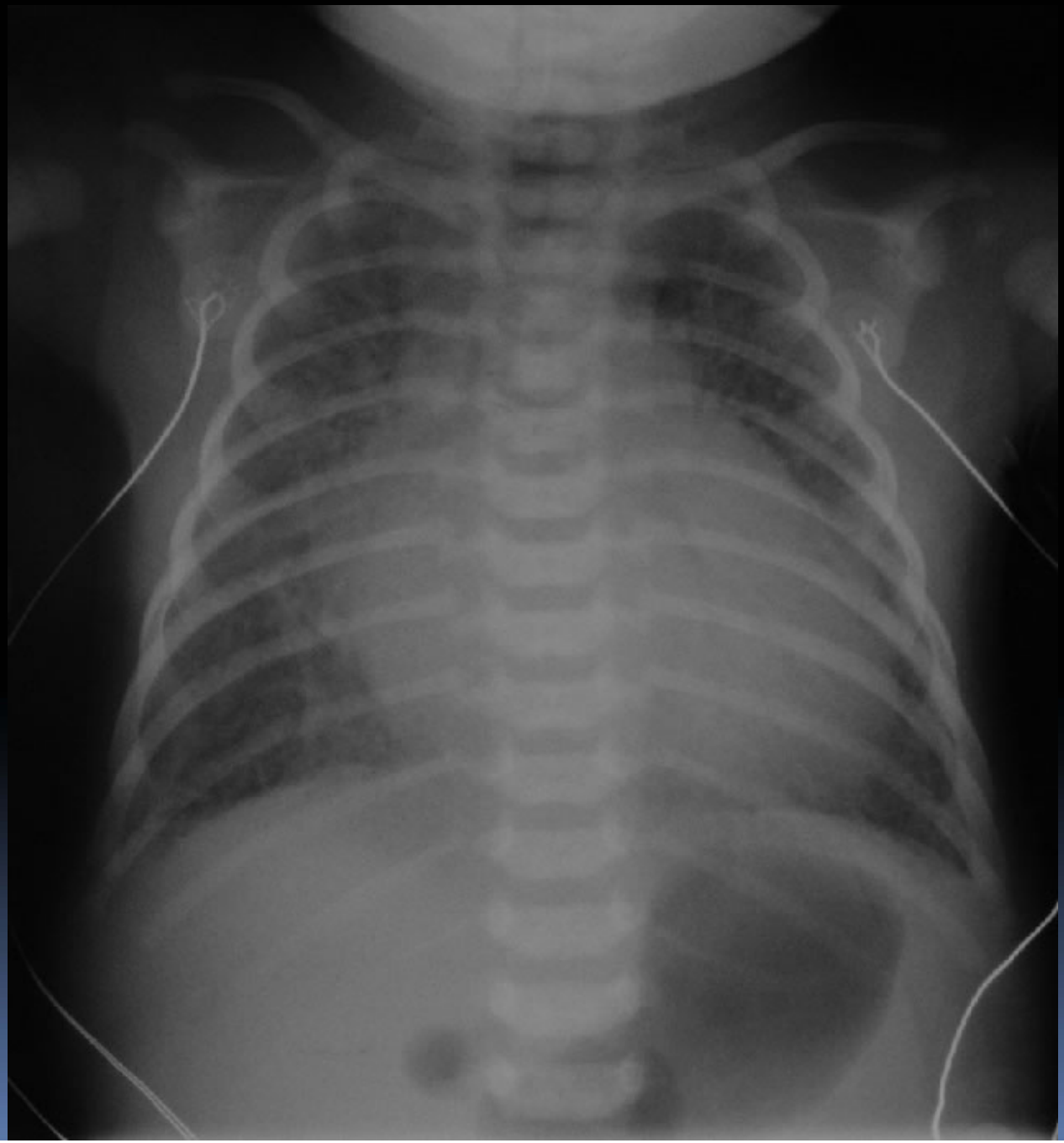

MITRAL VALVE ATRESIA
HYPOLASTIC LEFT VENTRICLE

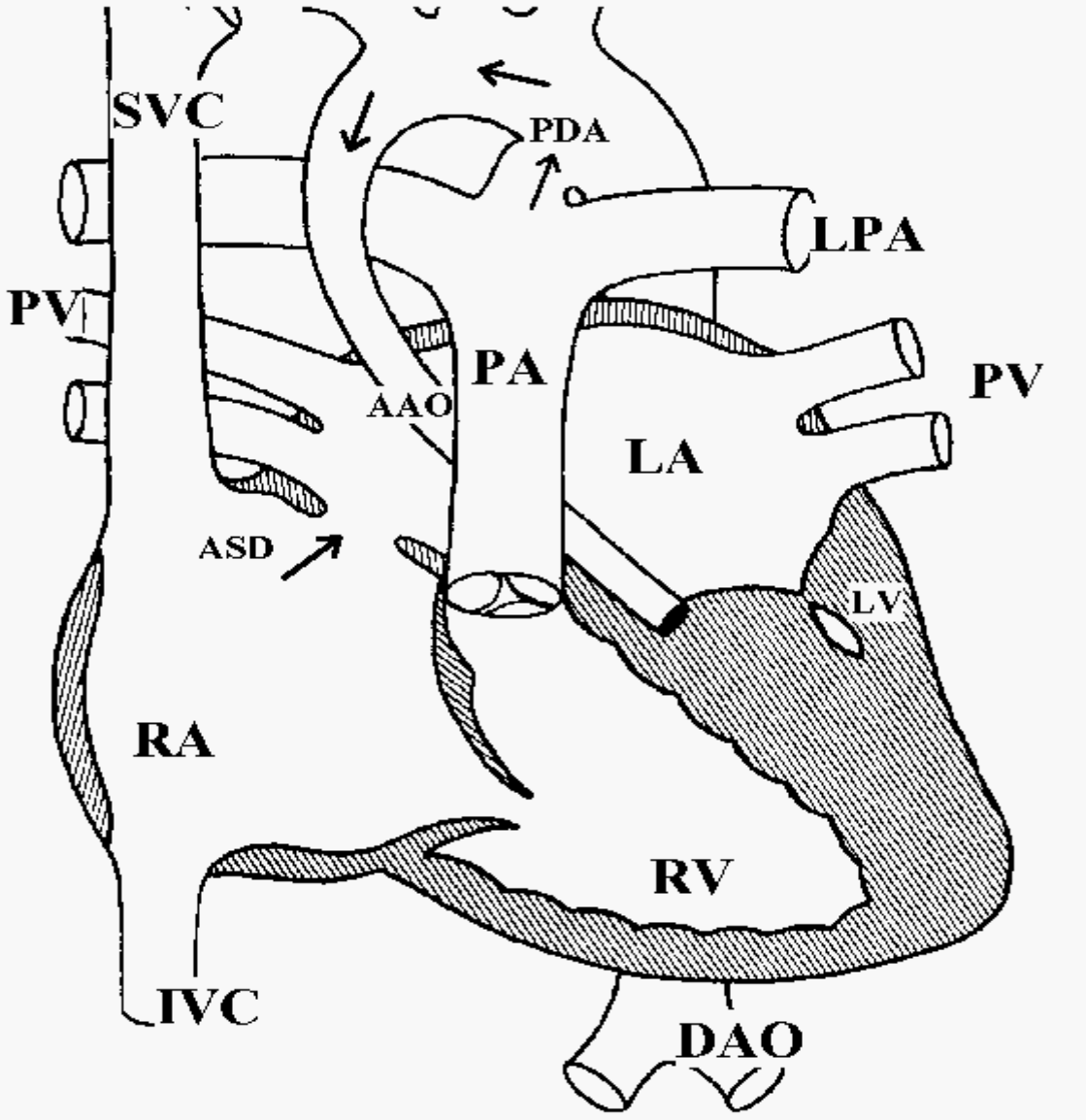

HYPOPLASTIC LEFT HEART SYNDROME

1% of all CHD, 9% of all CHD detected in nursery

Most common cause of death from CHD in neonatal period

HYPOPLASTIC LEFT HEART SYNDROME

Clinical Presentation

- Initially look ok.
- Dyspnea, cyanosis may not be obvious, usually tachypneic
- Second heart sound- loud single
- Murmur is usually absent
- Tachycardia, hepatomegaly, gallop, pulmonary rales, weak pulses, cold extremities

HYPOPLASTIC LEFT HEART SYNDROME

Therapy

- PGE1
- RA!, no O2
- Maintain NL pH-7.35, PCO2 40-45, Sats 75-85%
- Need UAC, UVC
- Avoid intubation and do not intubate for transfer

Next Case:

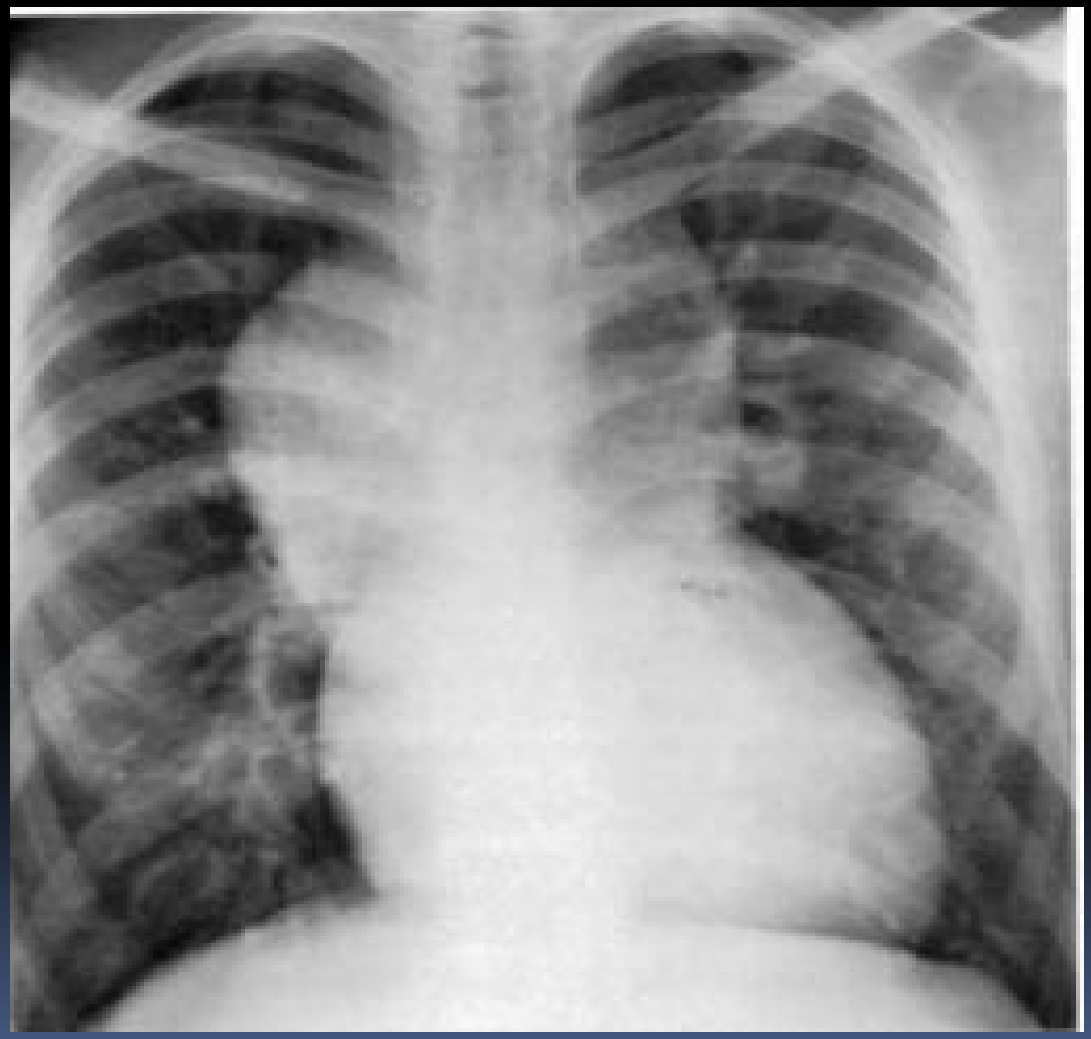

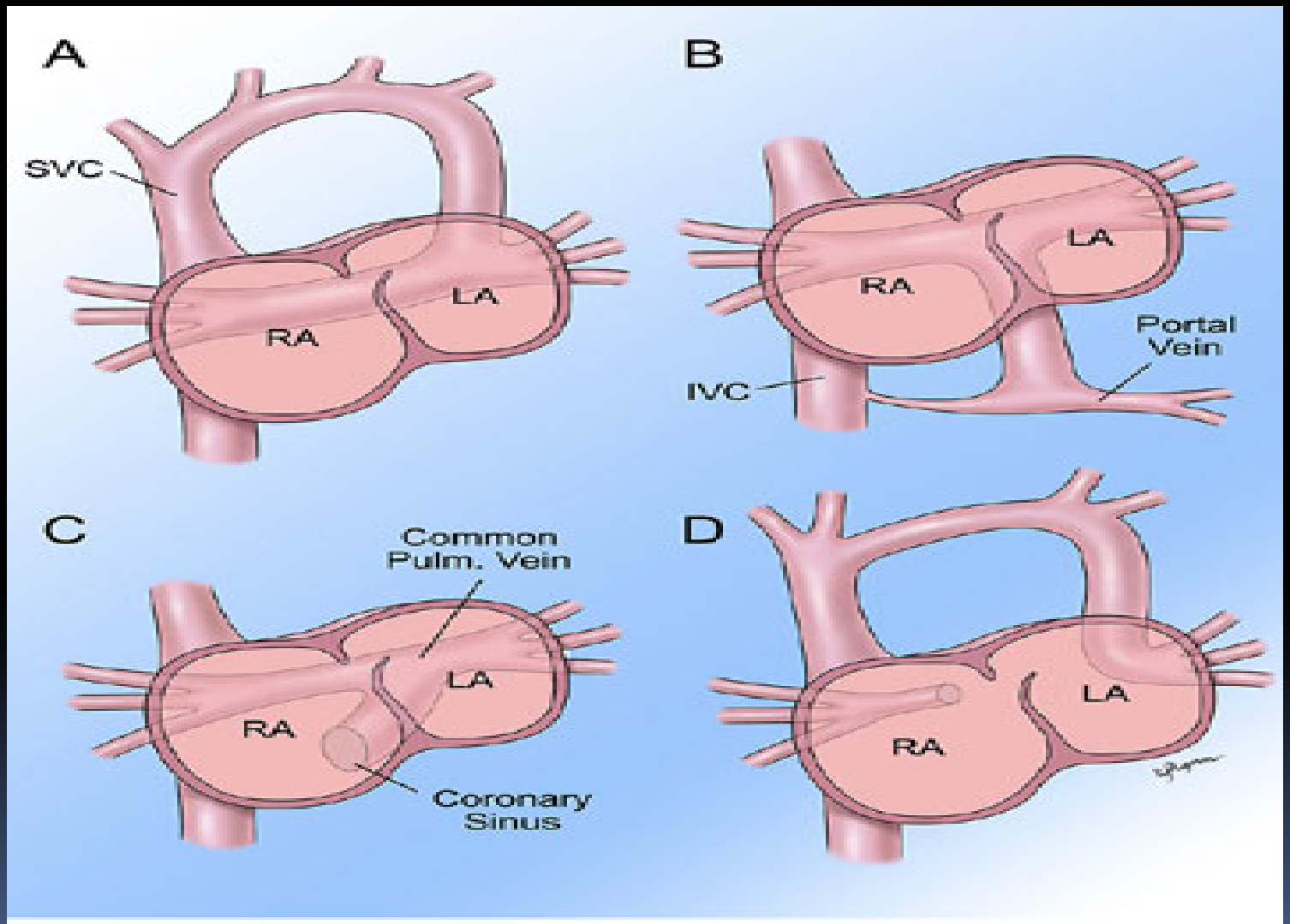

Children's Hospital Boston

Cyanotic CHD:

- Is it cyanosis.
- Is pt comfortable.
- Does he need PGE
- Does he need oxygen

Big Blue BOY

24 hours old

Sat 92 %, mild tachypnea

X Ray

MORE CYANOTIC NEWBORNS: CXR 1

The ECG is "unremarkable for a newborn"

This CXR demonstrates:

A. Transposition of the great vessels
B. Tetralogy of Fallot
C. Total anomalous pulmonary venous return
D. Tricuspid atresia
E. Pulmonary atresia with intact septum

MORE CYANOTIC NEWBORNS: CXR 1

The ECG is "unremarkable for a newborn"

This CXR demonstrates:

A. Transposition of the great vessels
B. Tetralogy of Fallot
C. Total anomalous pulmonary venous return
D. Tricuspid atresia
E. Pulmonary atresia with intact septum

The best way of mixing is :

1. Large PDA so PGE will save the baby
2. Large VSD
3. Moderate size ASD

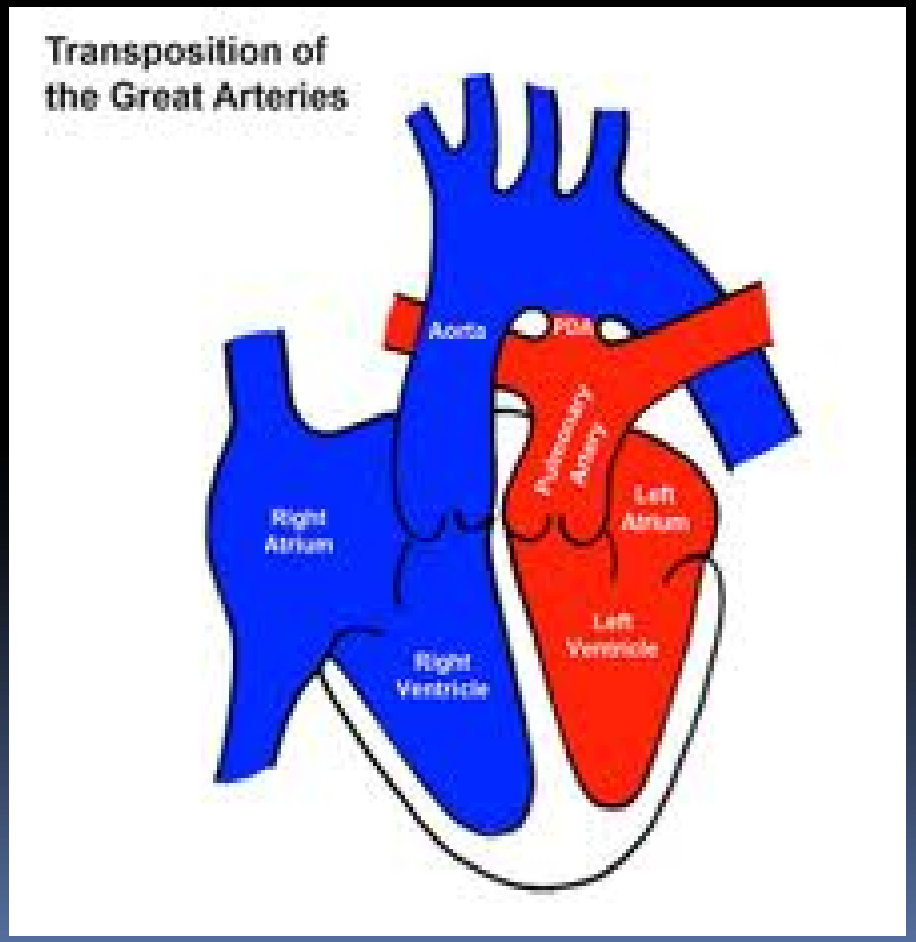

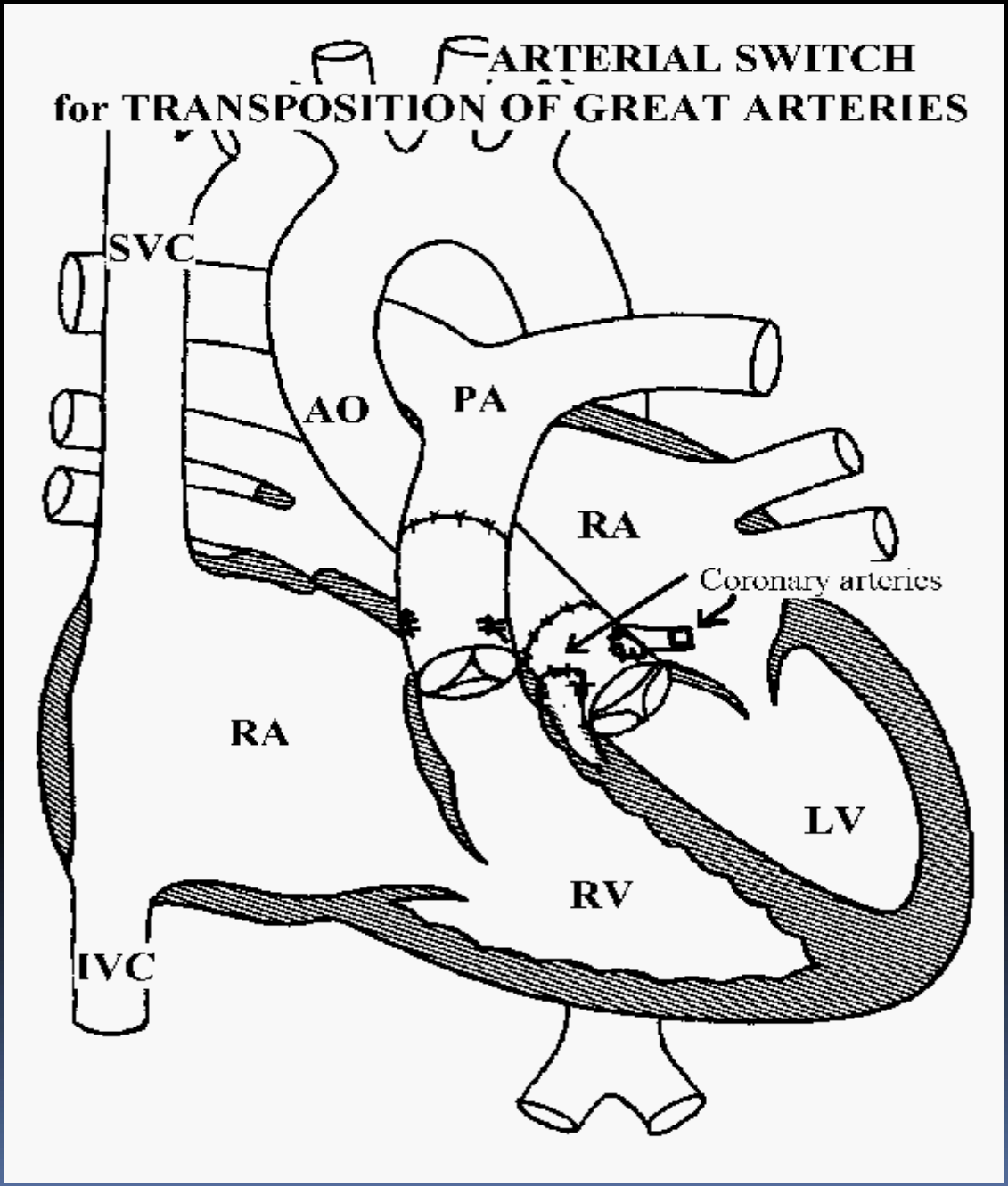
ARTERIAL SWITCH
for TRANSPOSITION OF GREAT ARTERIES
SVC
AO
PA
RA
Coronary arteries
RA
LV
RV
IVC

Cyanotic CHD :*Lesions with increased pulmonary blood flow*

- D-Transposition of the great arteries
- Truncus arteriosus
- Total anomalous pulmonary venous return
- DORV
- Single ventricle

Next Case

7 MONTH OLD WITH A MURMUR

- 7 months old.
- Mom stated he was blue when he wake up in the morning for few minutes.
- Murmur at 3 months old, seen by adult cardiologist (Small Premembranous VSD).

7 MONTH OLD WITH A MURMUR

- P/E and EKG: sat 85%, increase to 92 with 100% oxygen
  - RV impulse at the LLSB
  - A Systolic ejection click at the LUSB
  - A GR III/VI SEM LUSB.

- THIS ECG WAS OBTAINED.

You conclude:

1. The PE and EKG match the diagnosis
2. Send him to same cardiologist to avoid confusion

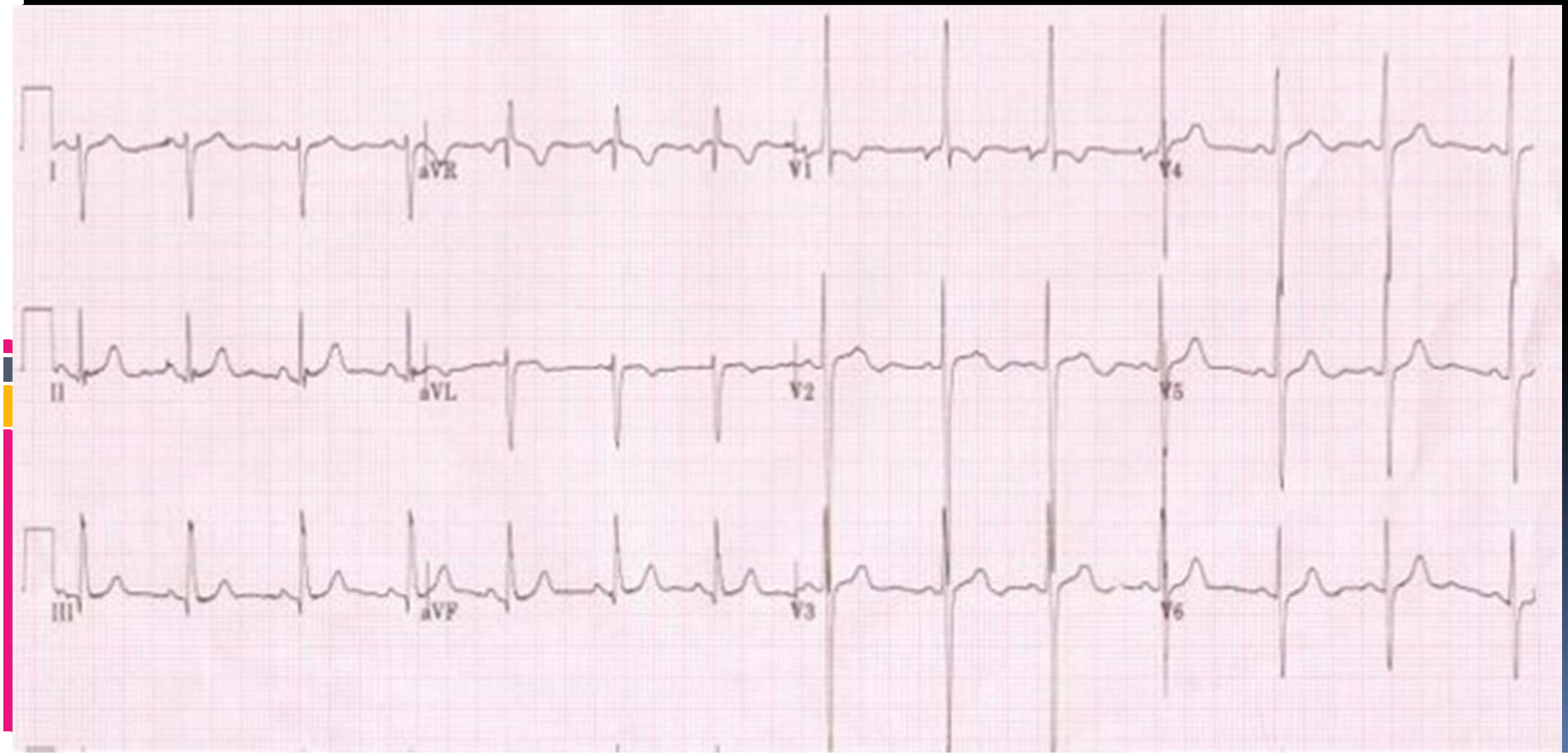

Chest X-ray

7 MONTH OLD WITH A MURMUR

- The next step for this patient is
  - Send him home and follow him in 3 months.
  - Tell the mom the VSD will close by 1 year
  - Call your friend pediatric cardiologist and ask him to see the pt urgently
  - Admit the pt to the hosp and treat him with oxygen

7 MONTH OLD WITH A MURMUR

- The next step for this patient is
  - Send him home and follow him in 3 months.
  - Tell the mom the VSD will close by 1 year
  - Call your friend pediatric cardiologist and ask him to see the pt urgently
  - Admit the pt to the hosp and treat him with oxygen

CXR

Echo finding

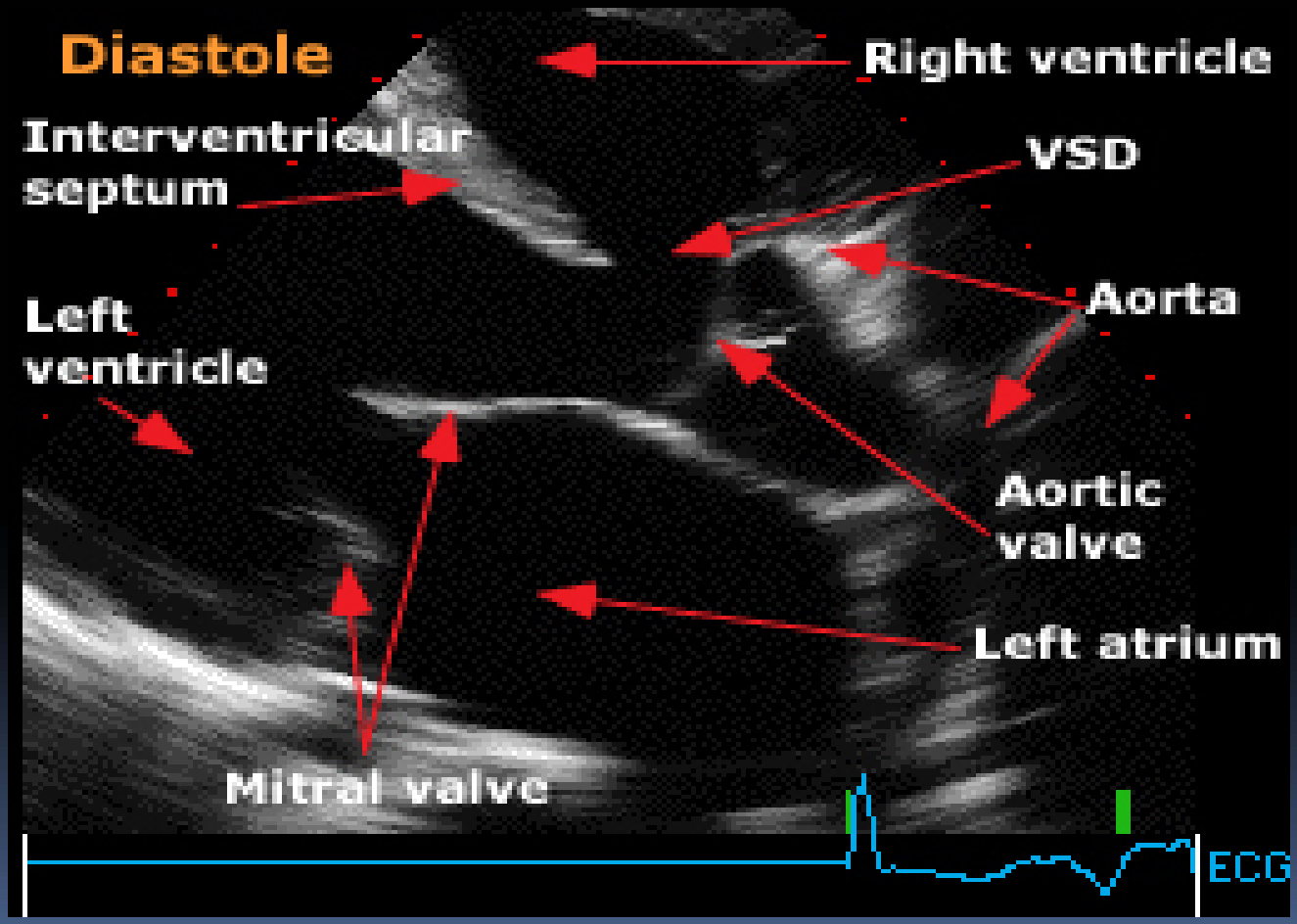

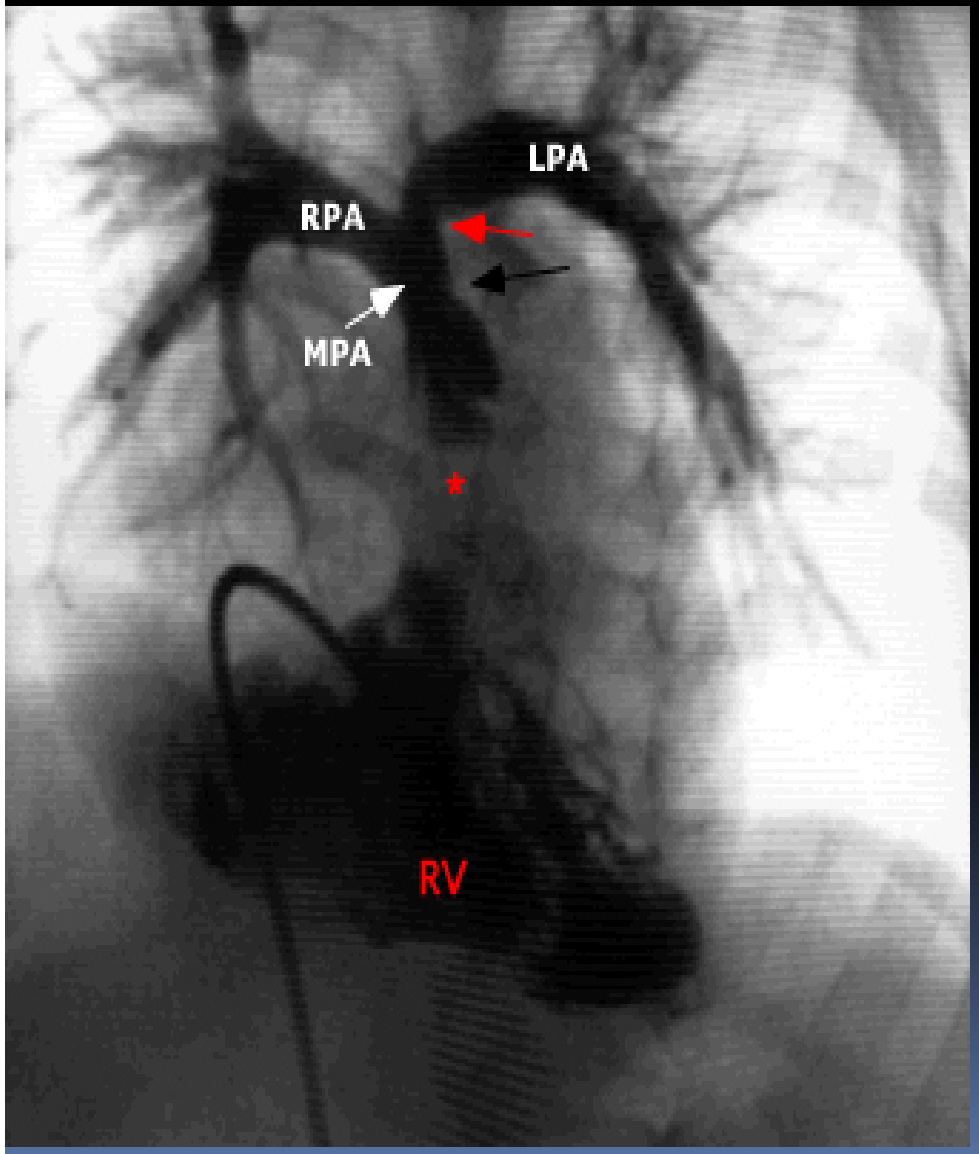
LPA
RPA
MPA
*
RV

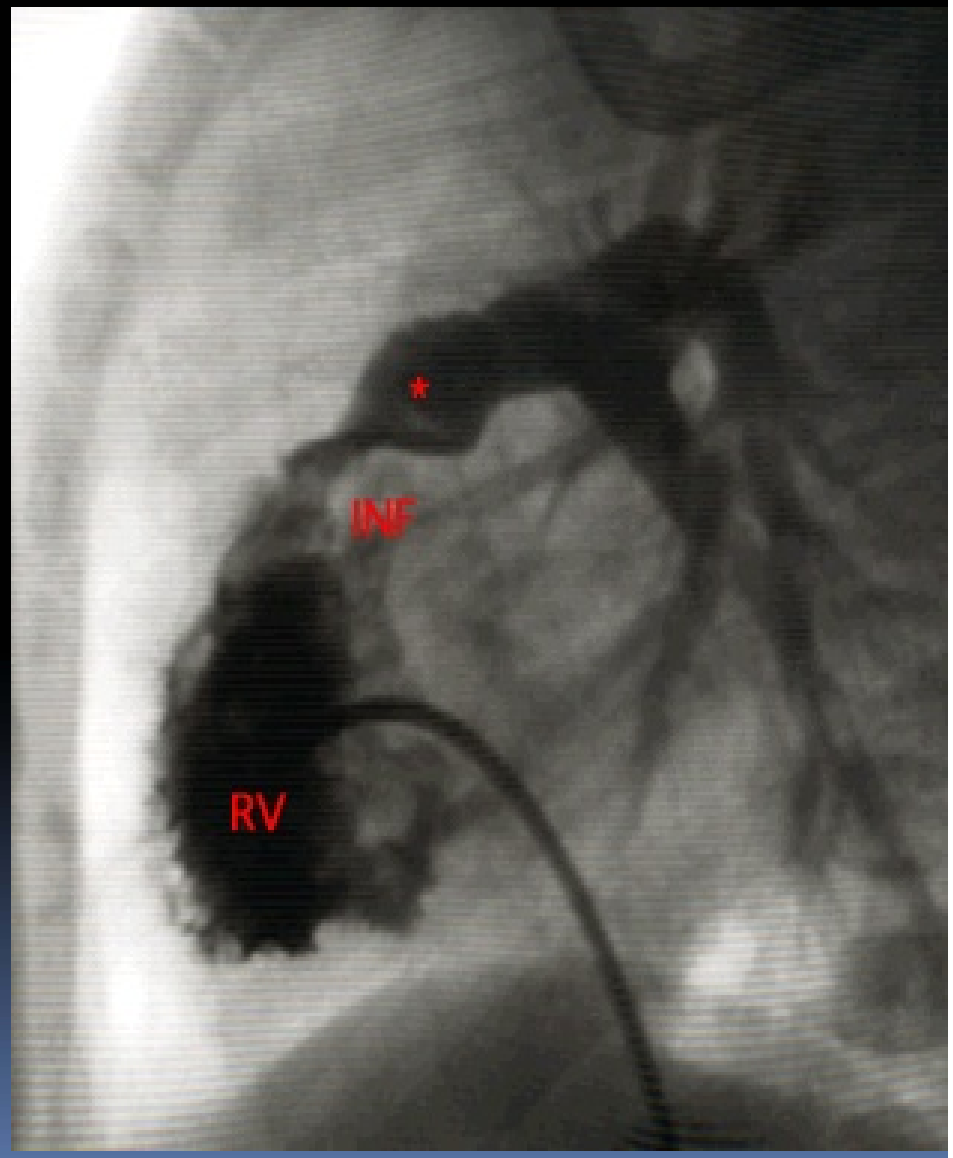
*
INF
RV

Questions?
Which country is this?