Before we are Born: Fetal Diagnosis of Congenital Heart Disease

Mohamed Sulaiman, MD

Pediatric cardiologist

Kidsheart: American Fetal & Children's Heart Center

Dubai Healthcare City, Dubai-UAE

First Pediatric Cardiology Symposium of Kidsheart

Disclosure

- No thing to disclose except:
  - I am the Co-founder of Kidsheart : American Fetal and Children heart center.

Objectives:

- Prenatal detection of CHD
- Indication for fetal echo.
- Program for fetal echocardiography in UAE.

Prenatal Ultrasound

1979 "of academic interest only. It should not be used to influence clinical judgment."

2013:

- diagnosis of CCVM as early as 12 weeks of gestation
- assess physiology of heart failure
- diagnosis of cardiac arrhythmias and guide treatment
- gain insight into the natural history of congenial and acquired cardiac defects

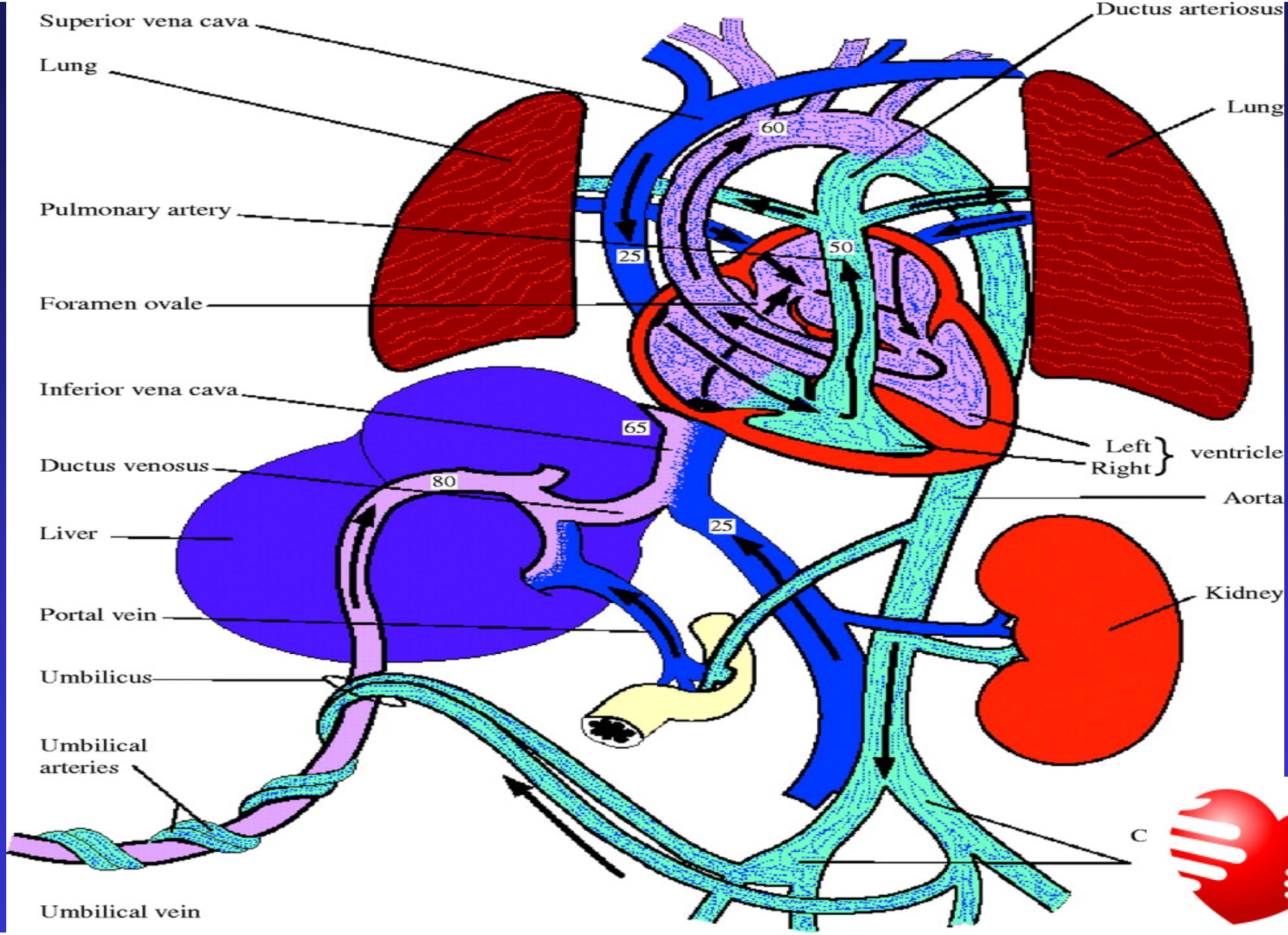
Superior vena cava
Lung
Pulmonary artery
Foramen ovale
Inferior vena cava
Ductus venosus
Liver
Portal vein
Umbilicus
Umbilical arteries
Umbilical vein
Ductus arteriosus
Lung
Left
Right
ventricle
Aorta
Kidney
60
25
50
65
80
25

Why screen for CHD

- CHD are the most common lethal congenital malformations and
- The most common congenital defect (8/1000 live births)
- The majority of CHD are from low risk pregnancies

An Ultrasound is an Ultrasound?

Level I: Fetal size and Gestational age
cardiac motion
OB/Technician (do and read)

Level II: Fetal Structural Survey
four chamber view

Perinatologist/Radiologist

Level III: Fetal Echocardiogram (Pediatric Cardiologist/some prenatologist)

Four Chamber View (Level II)

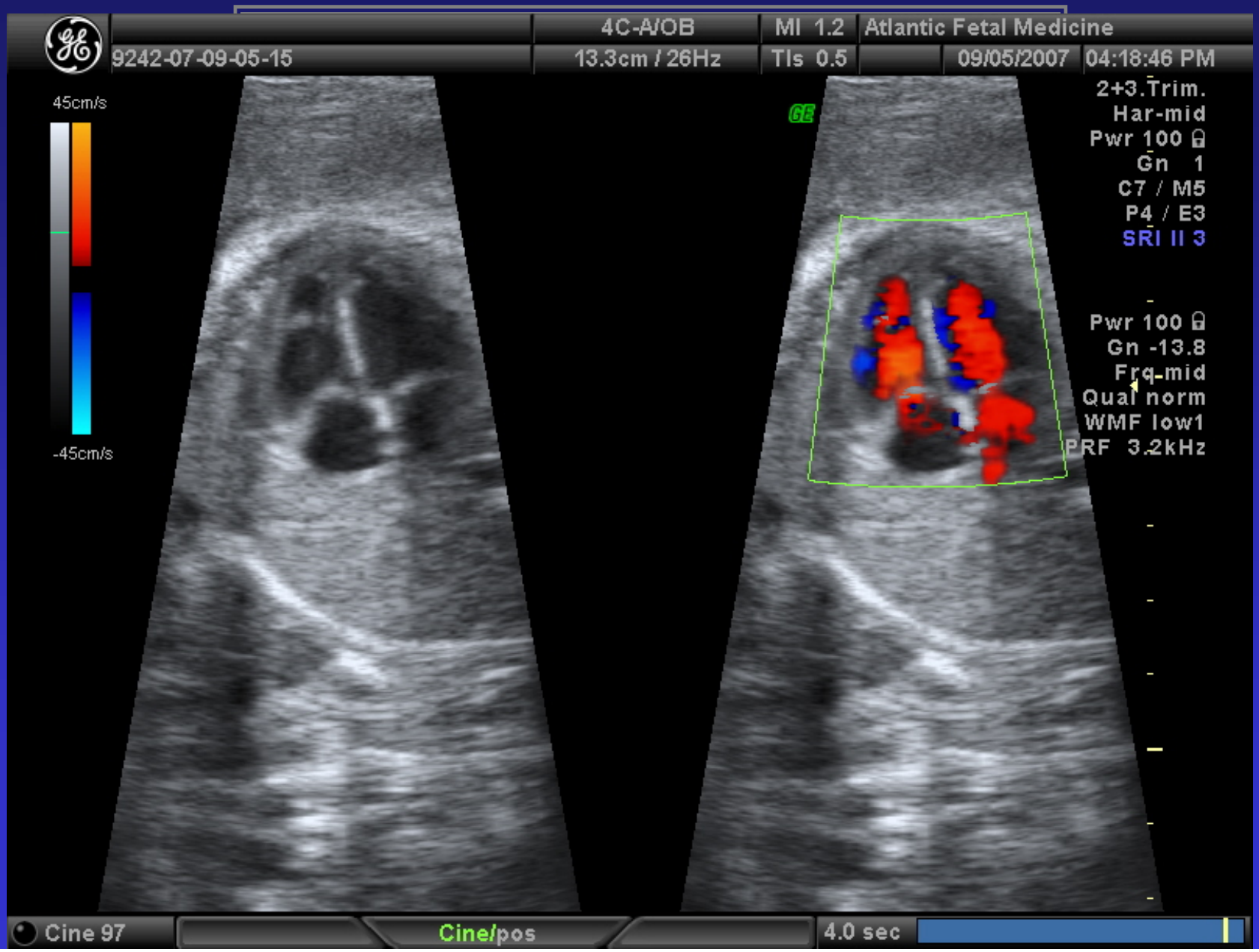

Detection of CHD : How Good is a Screening Ultrasound?

- Accurate 4 chamber view detects
  4 – 50 % of “serious” CHD.

- DOES NOT detect CHD with outflow tract anomalies that can be ductal dependent lesions

Abnormalities Detectable by 4 Chamber Screening Examination

- “Single” Ventricle
- Compete AV septal defect

Cardiac Surgery on "Single Ventricles" at UOC (July 1999 – April 2008)

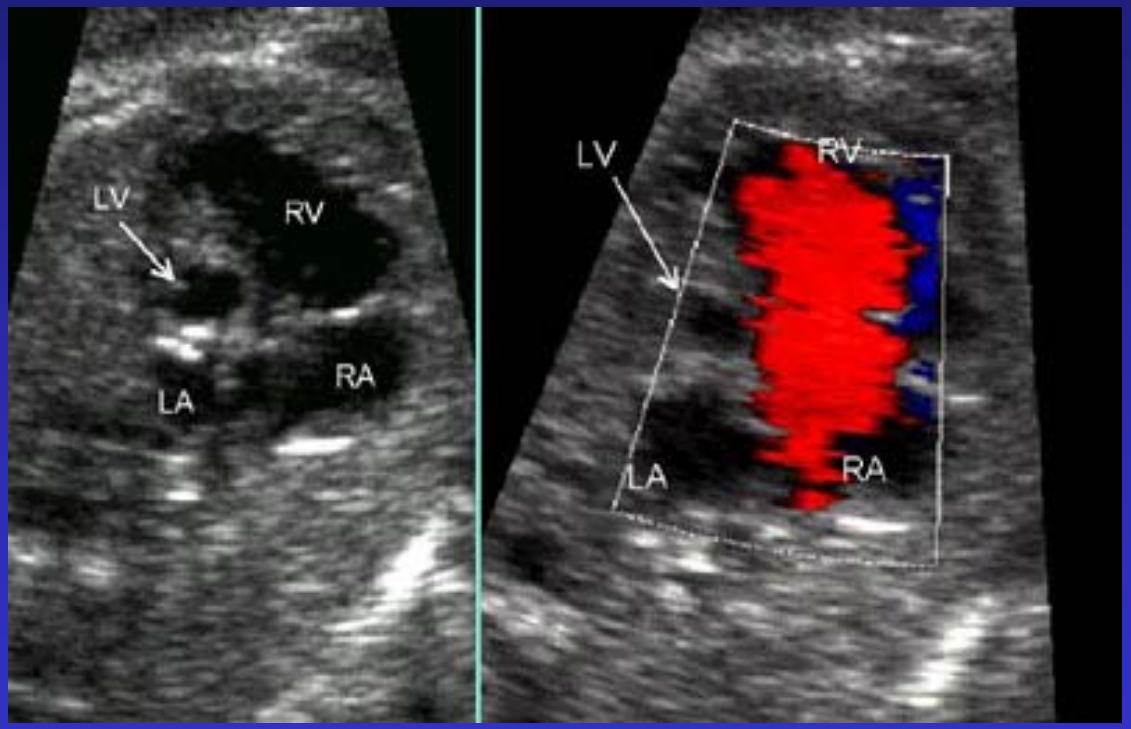

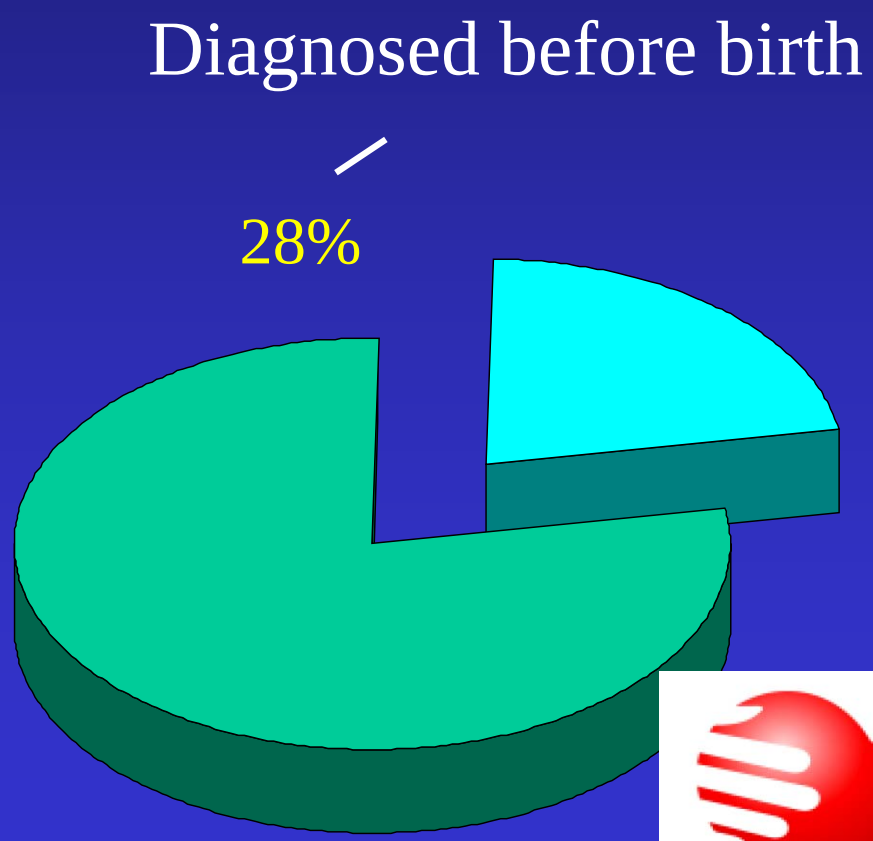

SV 11%
HLH 37%
HRJ 18%

Hypoplastic left heart Syndrom

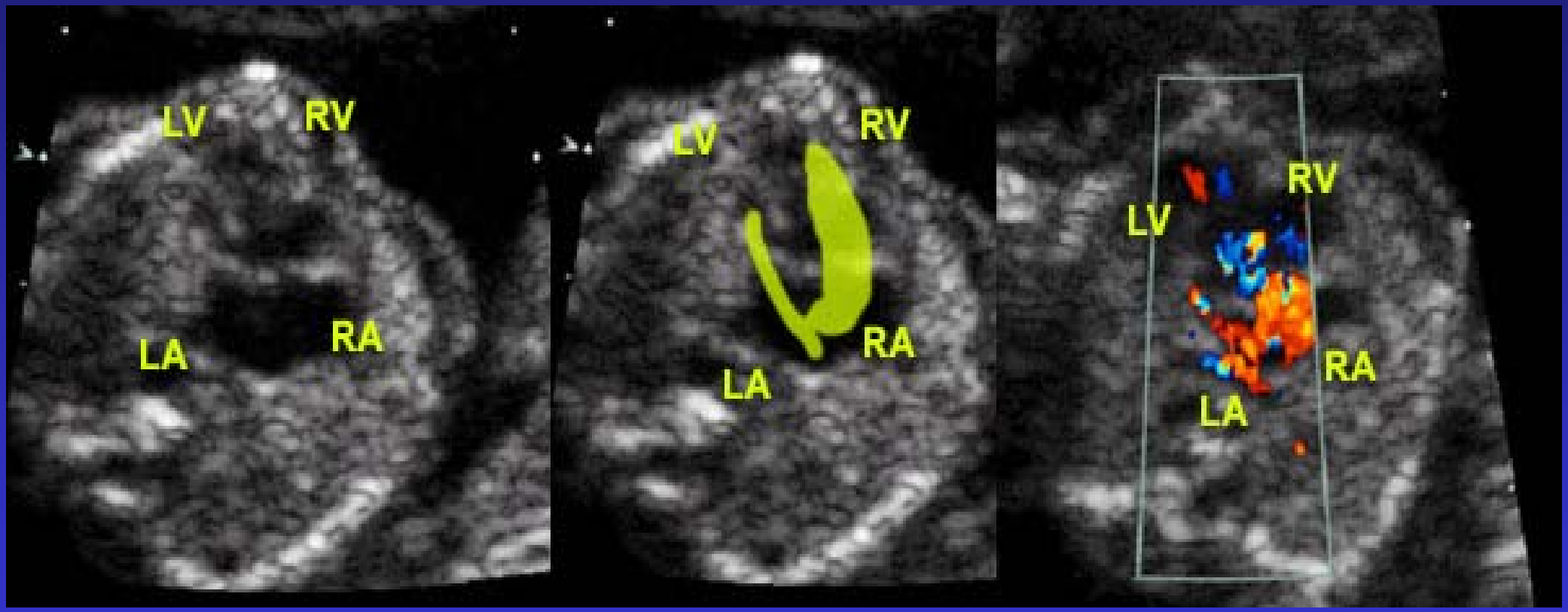

Cardiac Surgery on “Complete AV Septal Defect” at UOC (July 1999 – April 2008)

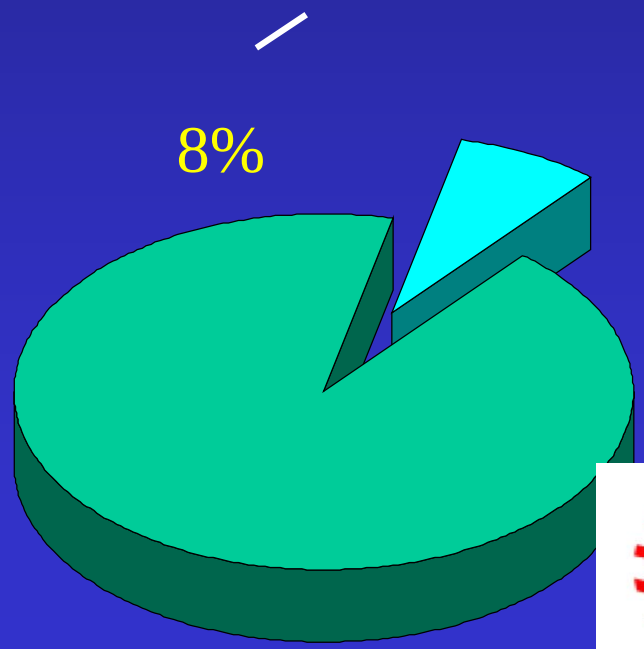

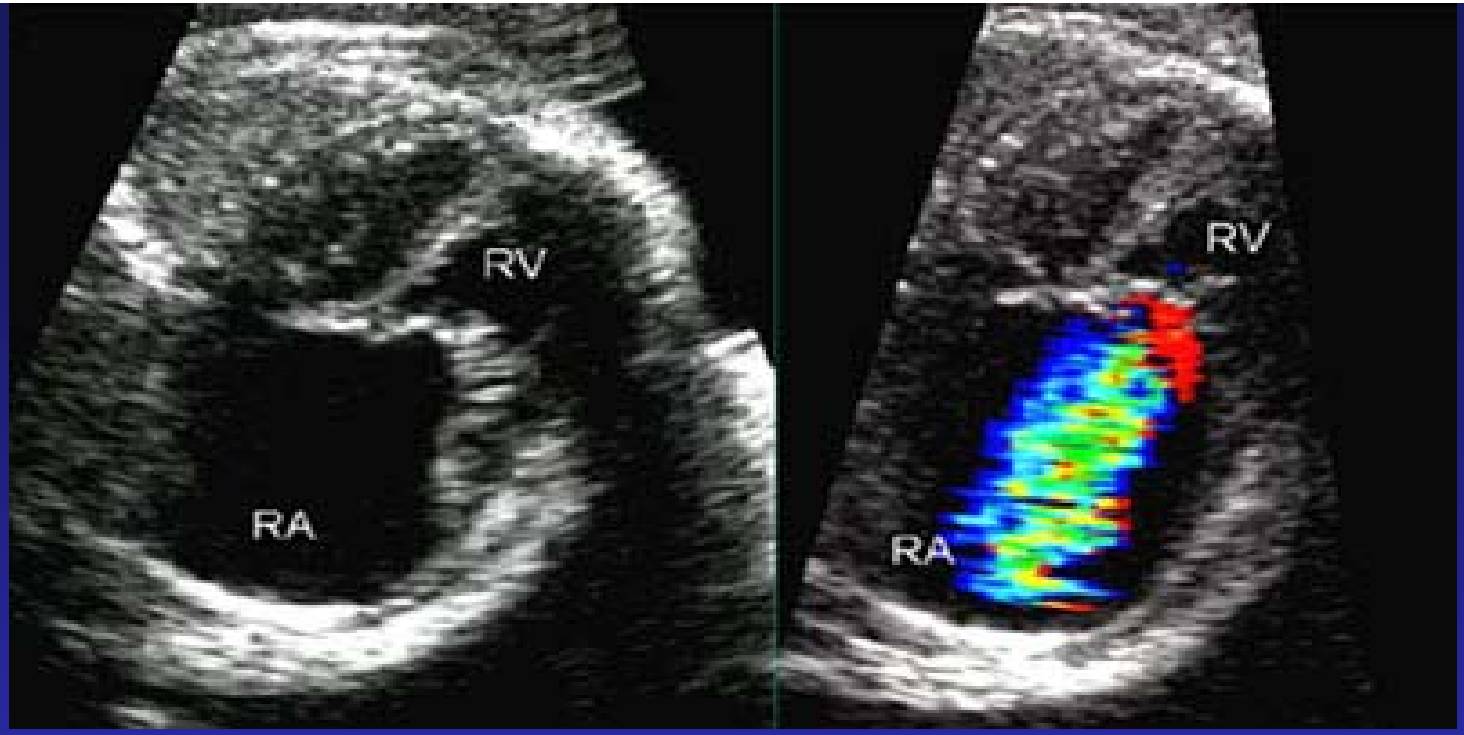

Tricuspid valve dysplasia

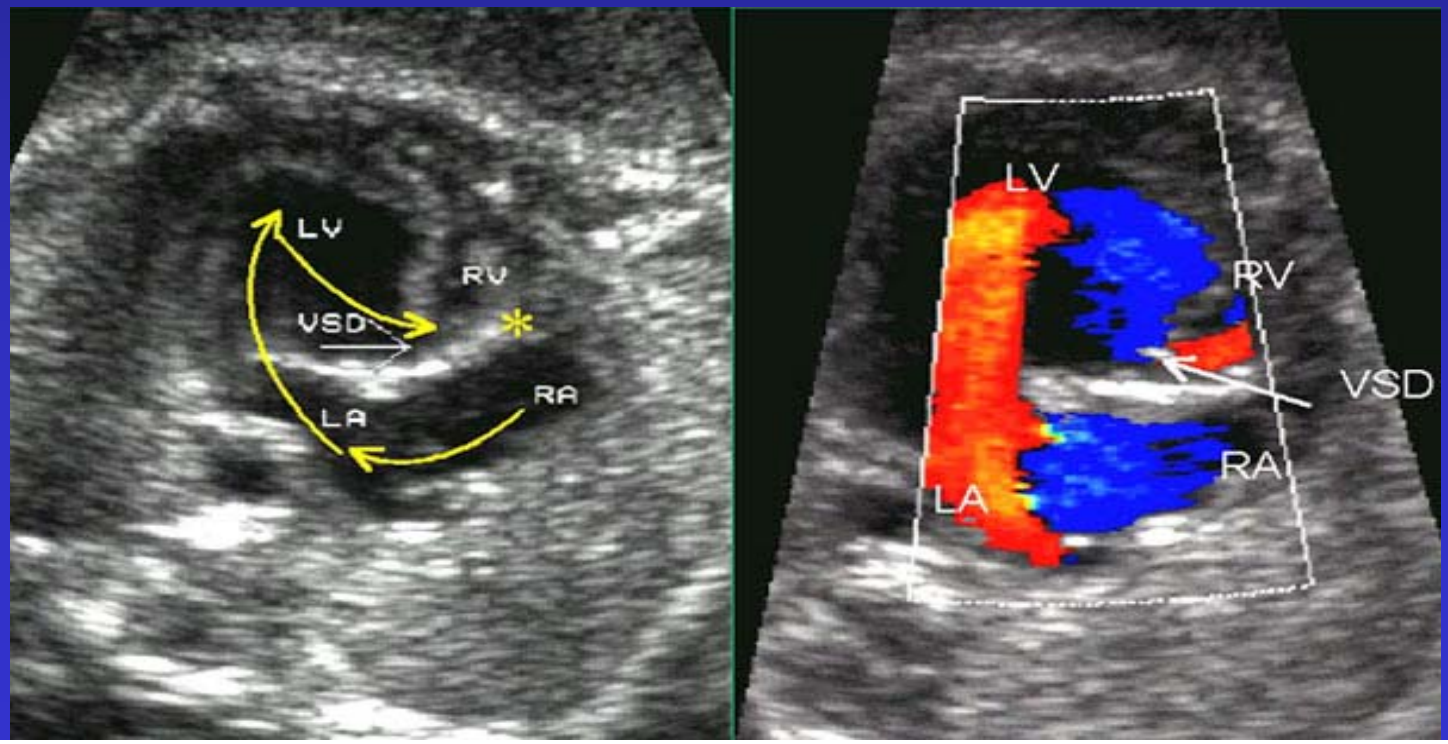

Tricuspid atresia

Detecting Fetal CHD:
Non-Selected Population at 18-24 Weeks

- 5347 fetuses evaluated with 4 chamber view PLUS follow-up scan if imaging suboptimal in first scan
- Scan time (US and 4-C heart) 30 minutes
- Detected 48% of CHD
- Incorporating great vessel views increased dectection to 78%

Achiron,R. Br Med J 304; 671-4 (1992)

Abnormalities Detectable by 4 Chamber Plus Outflow Tract Exams

- Transposition of the great vessels
- Tetralogy of Fallot
- Persistent truncus arteriosus
- Interrupted aortic arch

Improving the detection rate

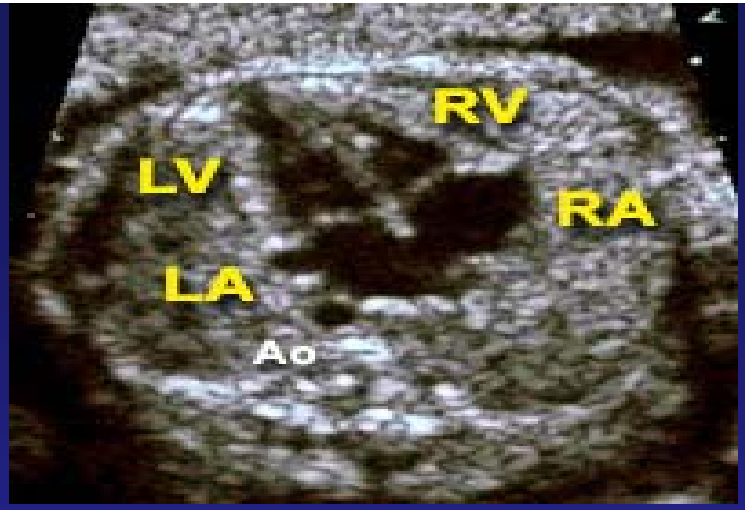

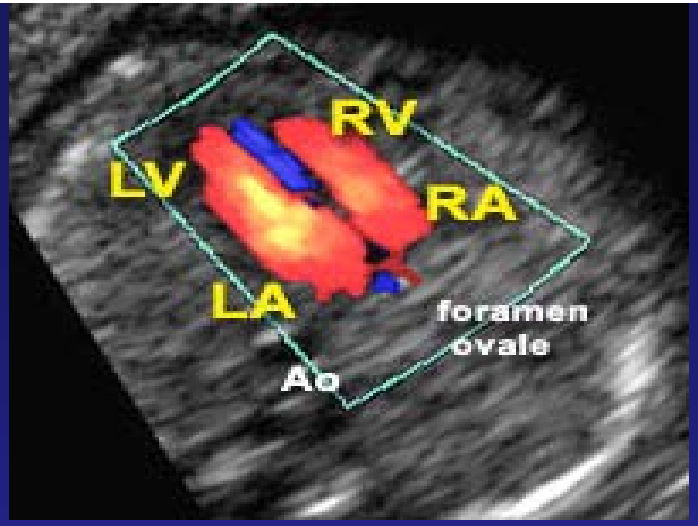

Adding the LVOT to the scan

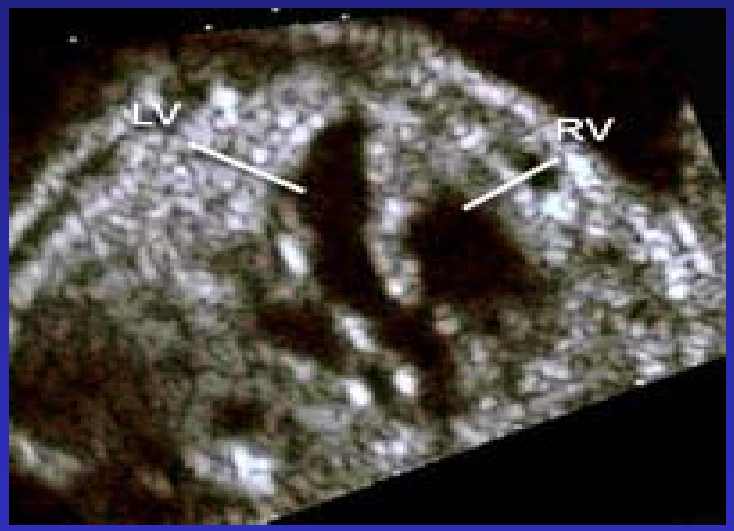

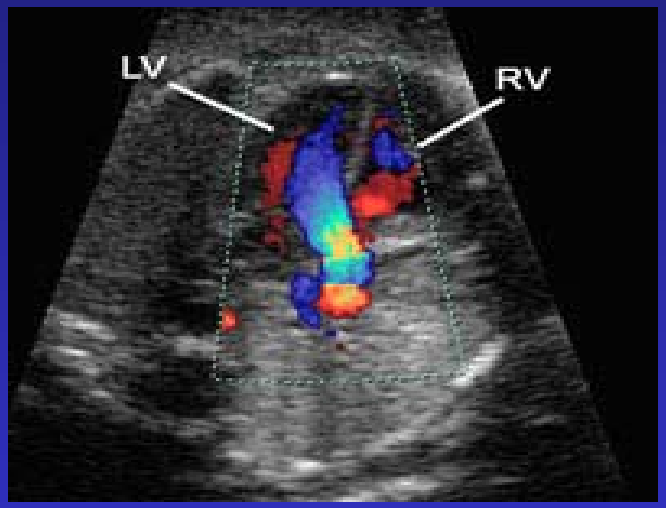

Adding the RVOT to the scan

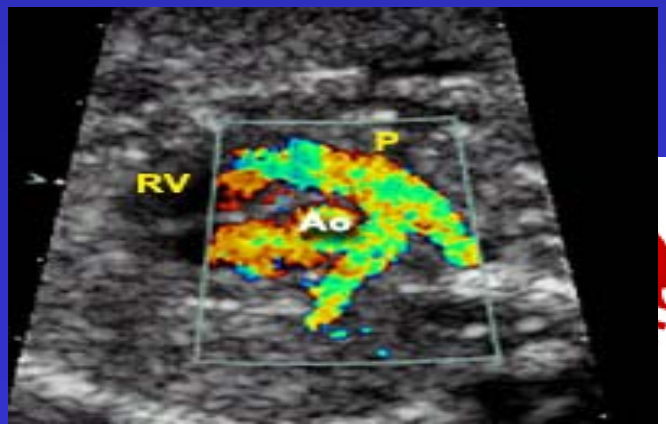

Transposition of Great Arteies

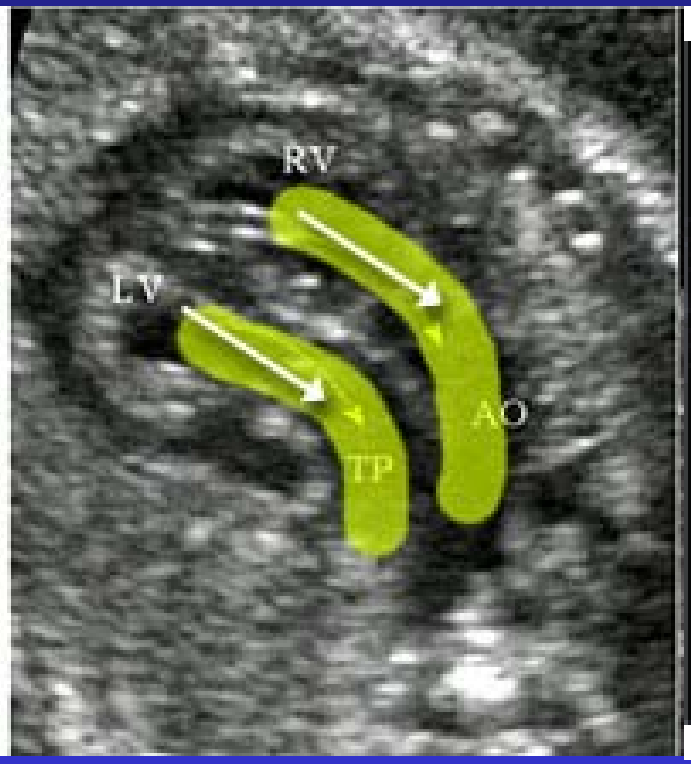

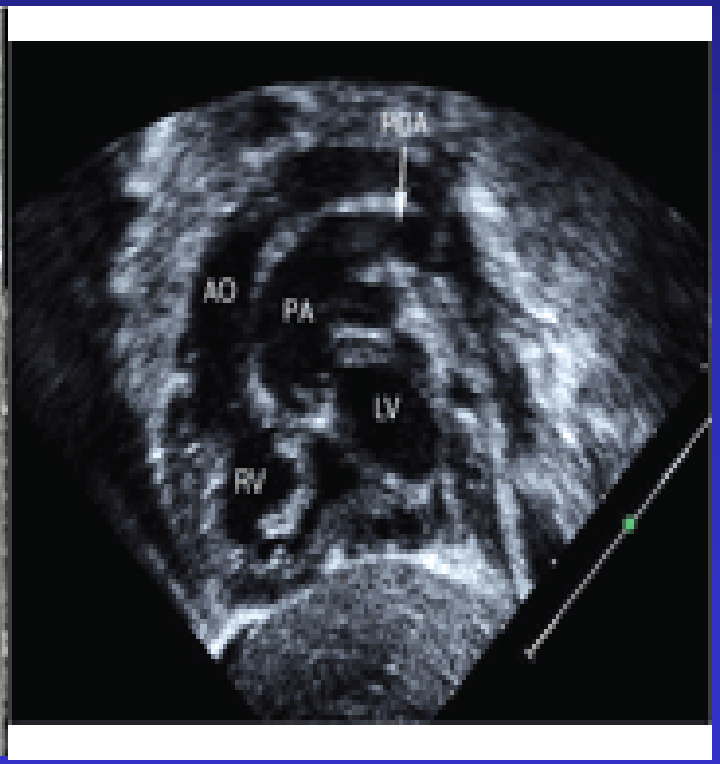

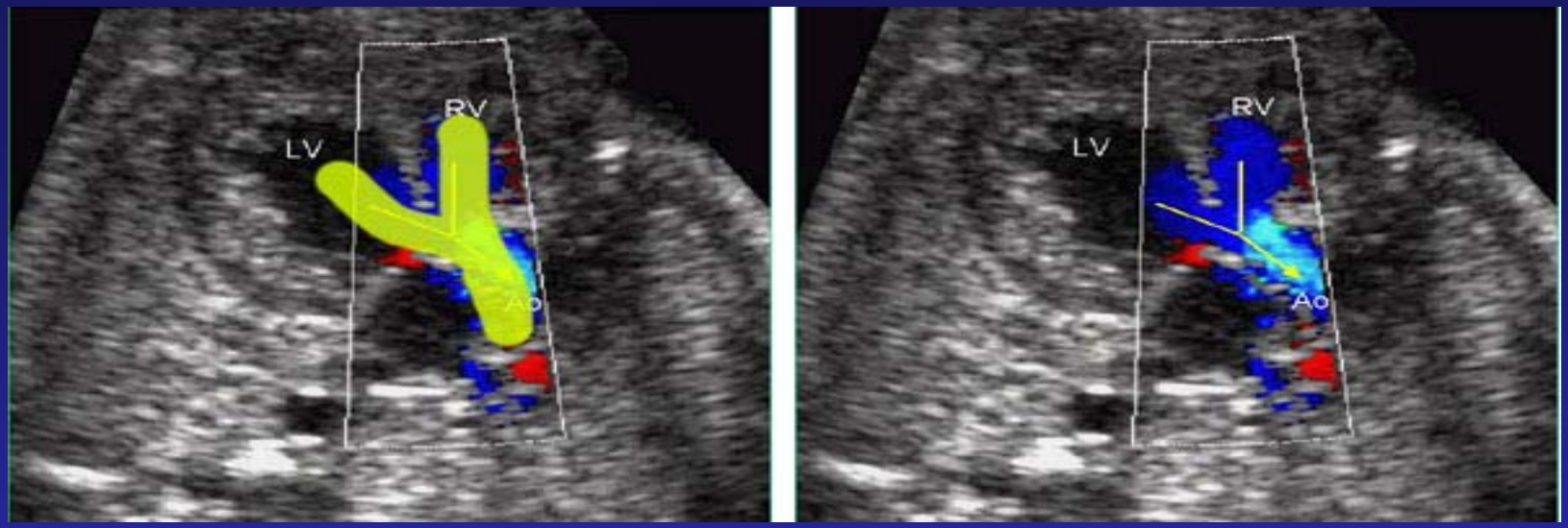

TOF

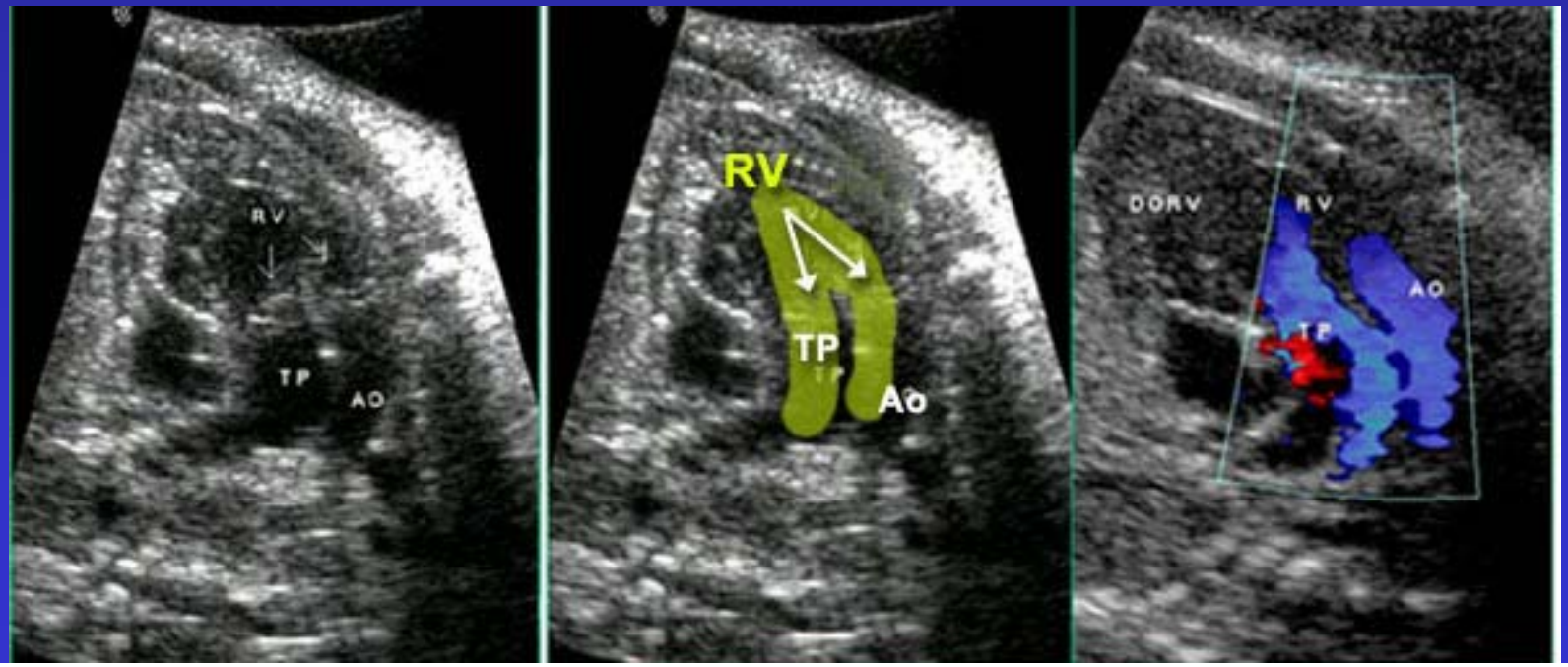

DORV

Rhabdomyoma

Pulsed Doppler

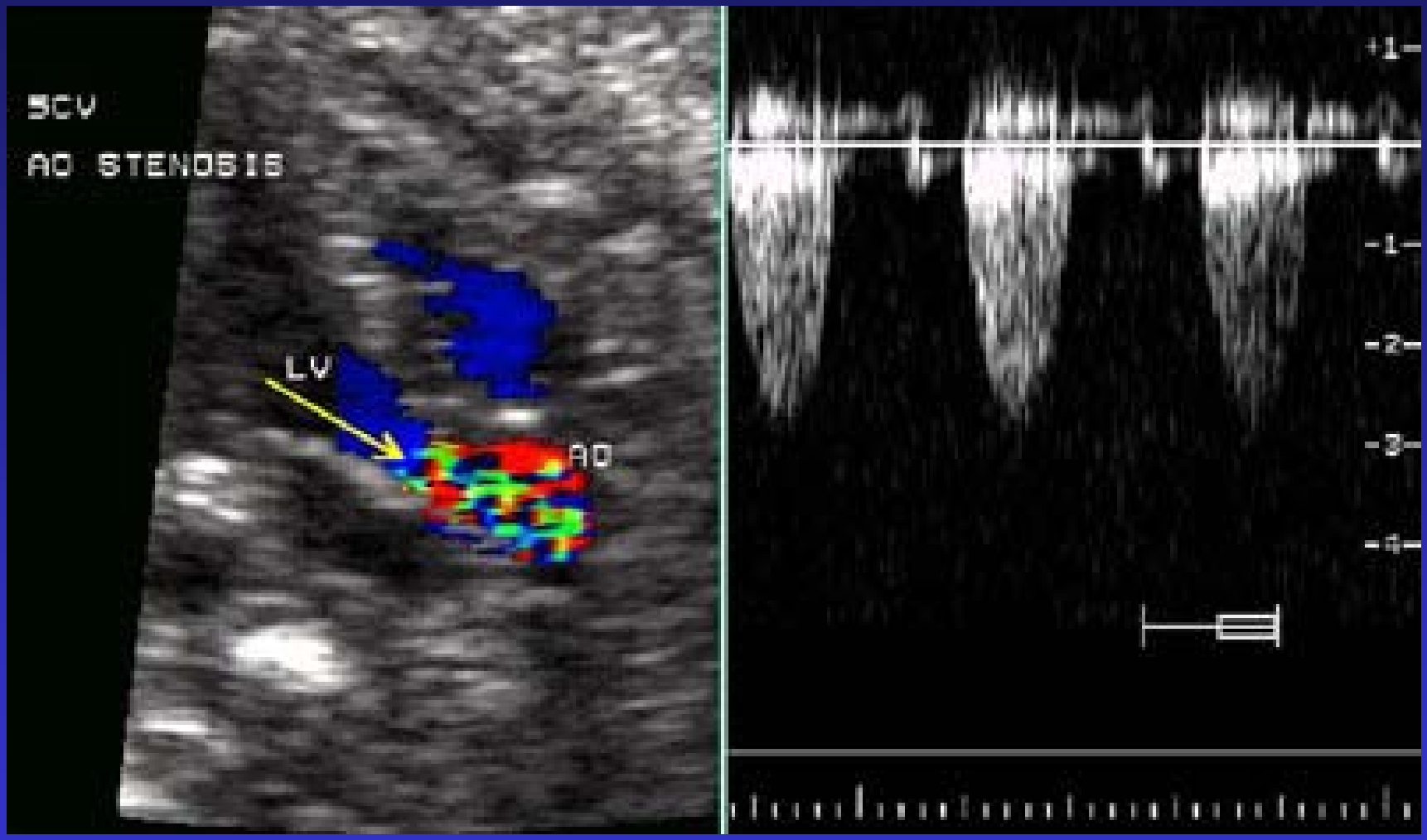

Color Flow Mapping

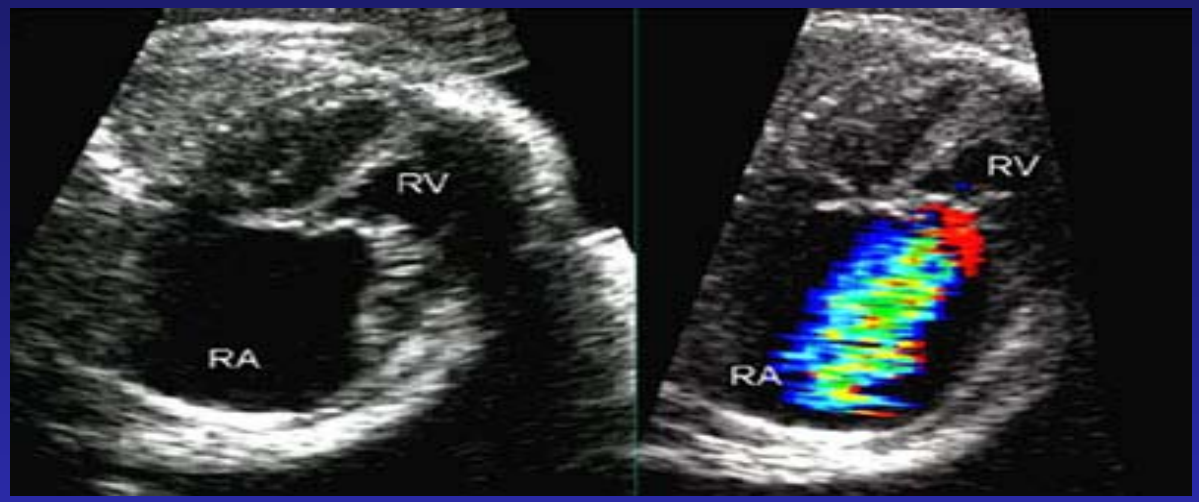

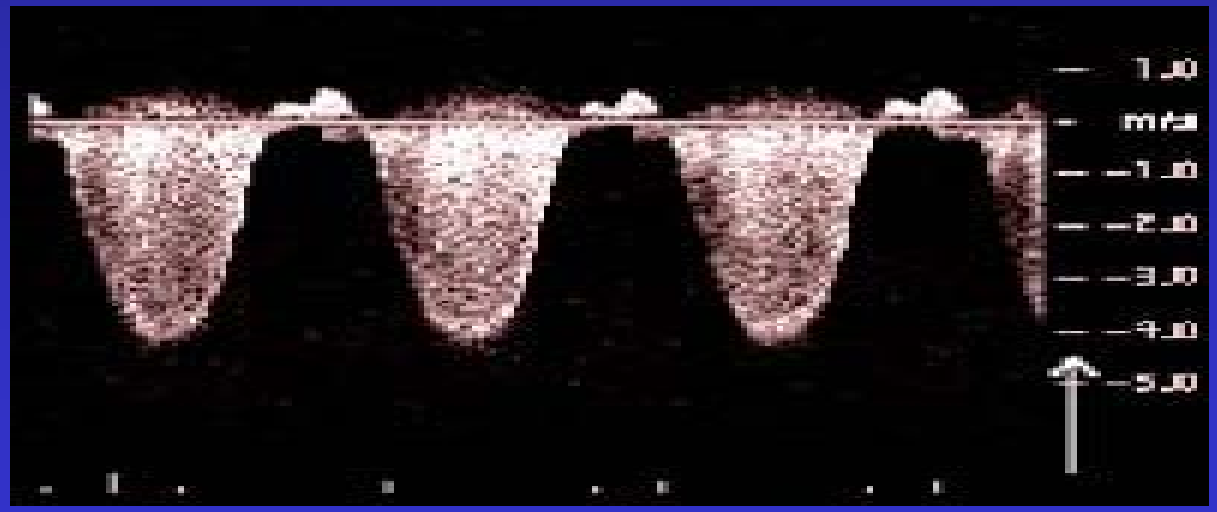

Detecting Fetal CHD:

- Unpublished data from Tawam hospital database
- Detection rate is 92 %. Initially was 87 %, then improved to 96 % in the last few years

Prenatal Detection of CHD

Risk factors for CHD

Maternal Risk

1. Diabetes
2. Anti-SSA/SSB (Ro/La) antibodies
3. Family hx CHD or cardiac syndrome
4. Teratogen exposure
5. Abnormal serum screening

Family History of CHD

- If either parent: risk is 2.5 – 4%
- If sibling: risk is 1 – 4 %
- If more than one sibling affected risk is 3 – 10%
- Highest recurrence risk is for left outflow obstruction
  - (AS, COA, HLH variants) : 10 – 15%

Family History of Syndromes with Cardiac Involvement

- Williams syndrome
- Marfan syndrome
- Tuberous sclerosis
- 22 q 11 Deletion syndrome
- Hypertrophic cardiomyopathy
- Noonan syndrome

Risk factors for CHD

Fetal Risk

1. Non-cardiac anomaly
2. Suspected cardiac defect (Very important)
3. Chromosome abnormalities.
4. Increased nuchal translucency
5. Hydrops fetalis
6. Arrhythmia

Chromosome Abnormalities and CHD

- Trisomy 21: 40%
  - CAVCD, VSD, TOF
- Trisomy 18: 90%
  - VSD, DORV, Polyvalver disease
- Trisomy 13: 80%
  - VSD

Miscellaneous

- Hydrops or isolated effusion
- Suspected twin: twin transfusion
- IUGR
- IVF

Abnormal Rate or Rhythm

- Bradycardia
  - HR < 100 bpm
- Tacycardia
  - HR > 180 bpm
- Irregular rhythm

M – Mode and arrhythmia

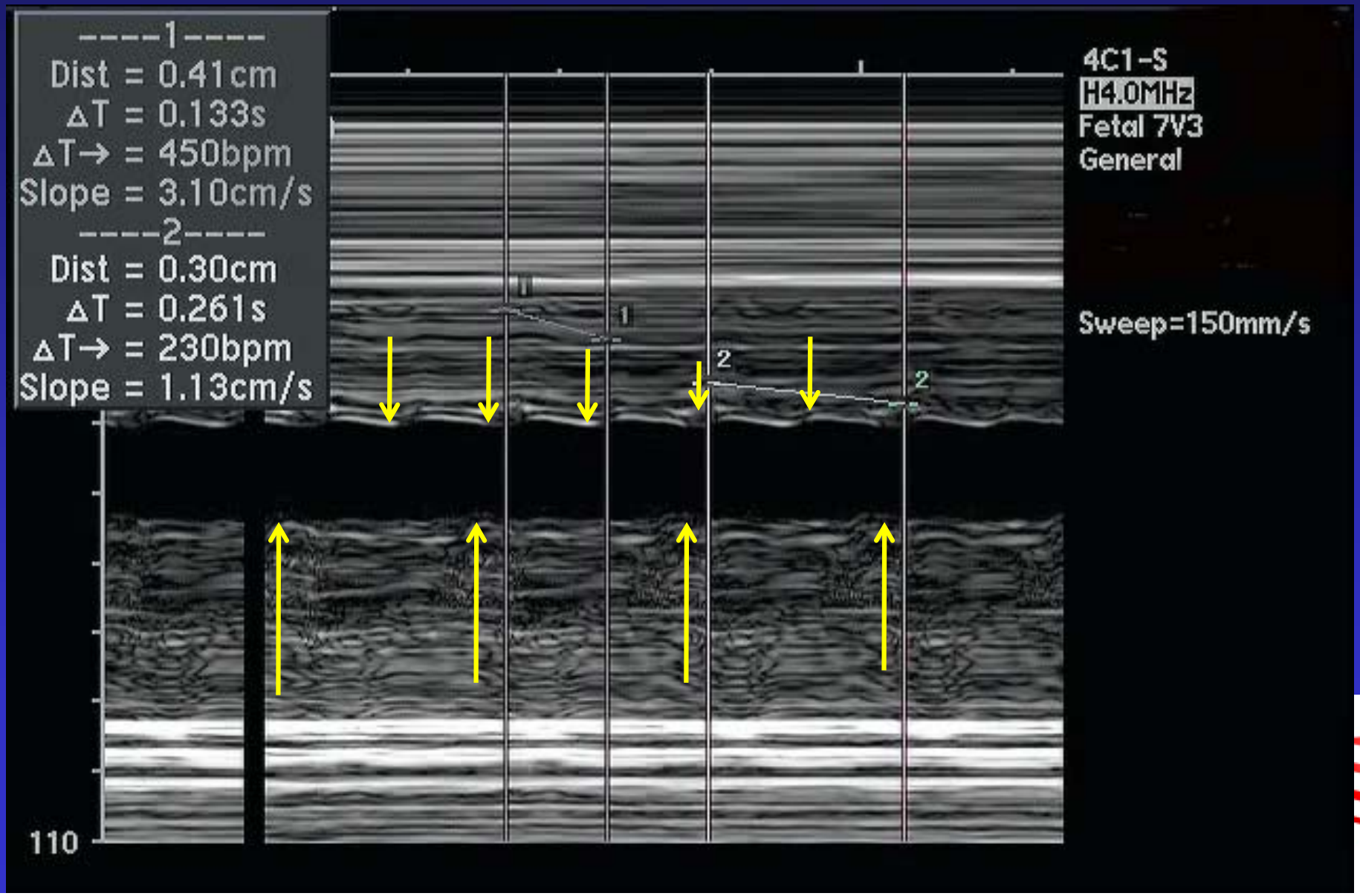

Advantages of Prenatal Diagnosis

- Parental reassurance
- Multidisciplinary counseling
- Therapeutic intervention

  (arrhythmias – not structural defects)
- IMPROVED OUTCOME
- No surprises after birth

Pediatric Fetal Cardiology program

Multidisciplinary team:

Pediatric Cardiologist

Prenatal OBGYN

NICU team

Pediatric Fetal Cardiology program

Why we are doing all of this ?

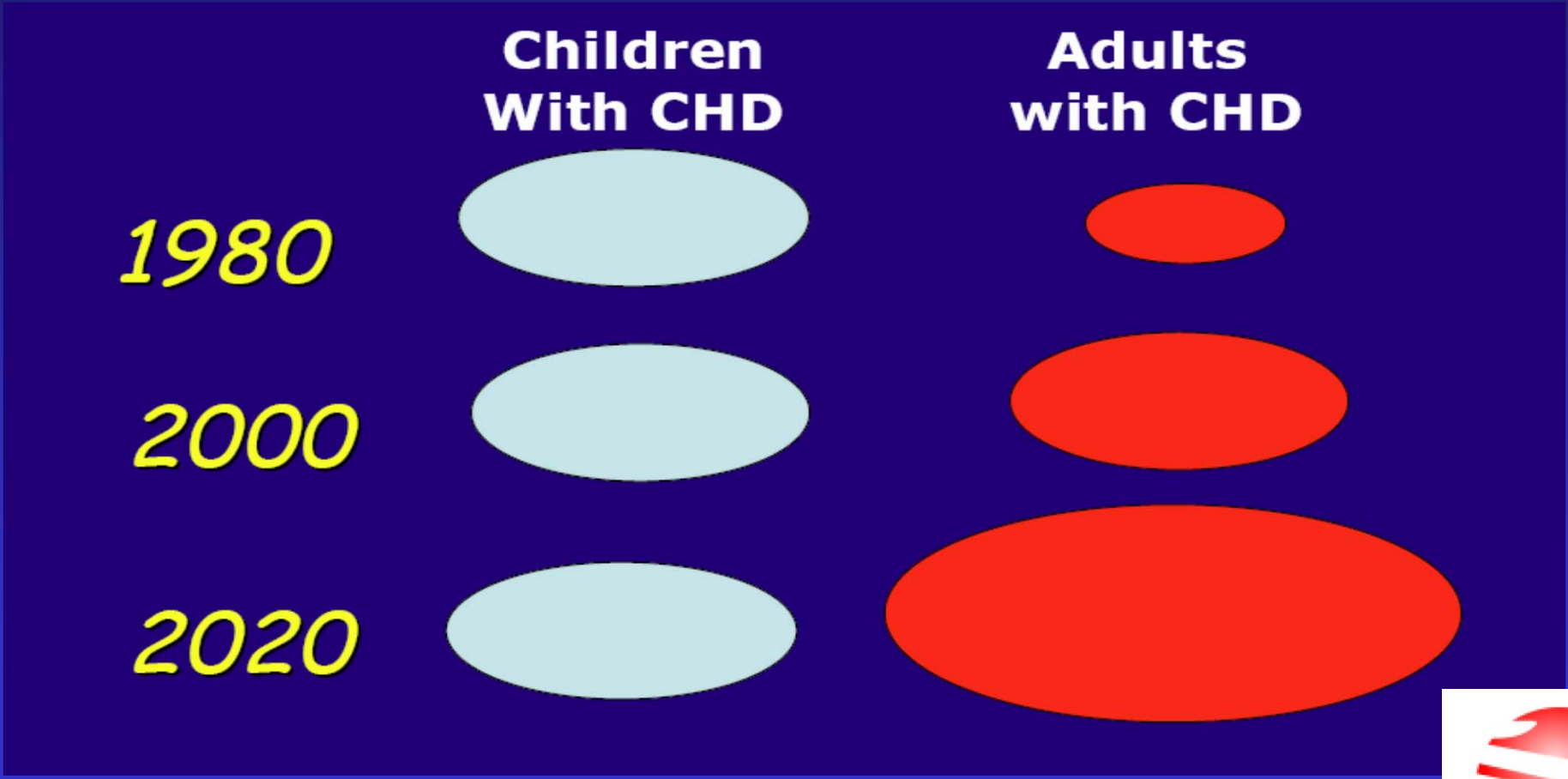

Thank you

Where is this Park located ?